

## Evaluation of the efficacy of vitamin D in the treatment of oral lichen planus: A double-blind randomized clinical trial

Zahra Delavarian MSc, DDS<sup>1</sup>, Zohreh Dalirsani MSc, DDS<sup>1</sup>,  
Zohreh Mousavi MD<sup>2</sup>, Mohammad Taghi Shakeri MD<sup>3</sup>,  
Hooshang Rafatpanah MD<sup>4</sup>, Farhad Seif PhD<sup>5</sup>, Asieh Rahimi MSc<sup>6</sup>

### Original Article

#### Abstract

**BACKGROUND AND AIM:** Oral lichen planus (OLP) is a chronic inflammatory and immune-mediated disease without a known etiology. Recent studies have indicated the role of vitamin D on immune system and proposed its anti-inflammatory effects. Present study aimed to evaluate the effect of vitamin D on the severity of pain, burning, and lesions of patients with OLP and serum levels of interleukin 6 (IL-6) and tumor necrosis factor alpha (TNF- $\alpha$ ) after the intervention.

**METHODS:** 28 patients with OLP with vitamin D deficiency or insufficiency participated in this randomized double-blind, placebo-controlled clinical trial. They were divided into the two groups of intervention (n = 13) and control (n = 15). Serum levels of TNF- $\alpha$ , vitamin D, and IL-6 were assessed before and 8 weeks after the treatment. The intervention and control groups were given one capsule of 50000 units of vitamin D and one placebo capsule weekly for 8 weeks, and they were also examined every other week, in terms of the severity of lesions (Thongprasom Index) and the severity of pain and burning [visual analog scale (VAS)]. The data analysis was carried out using SPSS statistical software and statistical tests included independent t-test, chi-square test, Mann-Whitney U-test, repeated measures test, and Pearson correlation coefficient test. Data were analyzed using SPSS software. The P-value < 0.05 was considered as significant.

**RESULTS:** The severity of lesions was significantly reduced in the intervention group (P = 0.043). After the treatment, the mean IL-6 levels significantly decreased in the intervention and control groups compared to pre-treatment conditions (P = 0.005 and P = 0.014, respectively). Moreover, the mean TNF- $\alpha$  concentrations significantly decreased only in the intervention group (P < 0.001).

**CONCLUSION:** Vitamin D reduced the severity of OLP lesions, IL-6, and TNF- $\alpha$ . Vitamin D can be suggested as adjuvant therapy for patients with OLP; however, further studies are required to confirm these effects.

**KEYWORDS:** Vitamin D; Oral Lichen Planus; Interleukin-6; Tumor Necrosis Factor; Visual Analog Scale

**Citation:** Delavarian Z, Dalirsani Z, Mousavi Z, Shakeri MT, Rafatpanah H, Seif F, et al. **Evaluation of the efficacy of vitamin D in the treatment of oral lichen planus: A double-blind randomized clinical trial.** J Oral Health Oral Epidemiol 2021; 10(2): 107-15.

Lichen planus is a chronic mucocutaneous immune-mediated disease. Various prevalence rates have been reported for oral lichen planus (OLP) in previous studies, ranging from 1% to 4%;<sup>1</sup> however, the prevalence of OLP was about 18.2% in patients who referred to Mashhad School of Dentistry,

Mashhad, Iran, in a period of 5 years.<sup>2</sup> Cell-mediated immune system, in particular CD8<sup>+</sup> T cells, plays an important role in the development of OLP.<sup>1</sup> Several specific and non-specific inflammatory mechanisms have been described, e.g., the accumulation and localization of CD8<sup>+</sup> T cells under epithelium and induction of apoptosis in basal epithelial

1- Professor, Oral and Maxillofacial Diseases Research Center, Mashhad University of Medical Sciences, Mashhad, Iran

2- Professor, Metabolic Syndrome Research Center, Mashhad University of Medical Sciences, Mashhad, Iran

3- Professor, Department of Epidemiology and Biostatistics, School of Health, Mashhad University of Medical Sciences, Mashhad, Iran

4- Professor, Immunology Research Center, Inflammation and Inflammatory Diseases Division, Mashhad University of Medical Sciences, Mashhad, Iran

5- Associate Professor, Department of Immunology and Allergy, Academic Center for Education, Culture, and Research, Tehran, Iran

6- Medical Laser Research Center, Academic Center for Education, Culture and Research, Tehran, Iran

Address for correspondence: Asieh Rahimi MSc; Medical Laser Research Center, Academic Center for Education, Culture and Research, Tehran, Iran; Email: dr.rahimi.79@gmail.com

cells and keratinocytes.<sup>3</sup>

Previous studies have also revealed an increase in the production of proinflammatory cytokines in OLP.<sup>4</sup> Proinflammatory cytokines such as interleukin-12 (IL-12), IL-2, tumor necrosis factor alpha (TNF- $\alpha$ ), and interferon gamma (IFN- $\gamma$ ) are involved in immune responses, especially cell-mediated immunity.<sup>4</sup> These cytokines give rise to the infiltration of monocytes, macrophages, and lymphocytes, leading to increased production of inflammatory cytokines.<sup>5</sup> For example, IL-1 beta (IL-1 $\beta$ ) increases the production of TNF- $\alpha$ , IL-6, and granulocyte-macrophage colony-stimulating factor (GM-CSF) from keratinocytes and tissue-infiltrating mononuclear cells (TIMC) in OLP.<sup>4</sup> Two cytokines of IL-6 and IL-8 are increased in the serum of patients with OLP. Moreover, many researchers have observed increased levels of salivary and serum TNF- $\alpha$  in patients with OLP.<sup>5,6</sup> Accordingly, they appear to be useful indicators of measuring the disease activity and the therapeutic effects of administered drugs.<sup>5</sup>

Epidemiologic studies in different populations have indicated a significant relationship between vitamin D deficiency and inflammatory or autoimmune diseases as well as its pharmacological role in regulating immune responses.<sup>7,8</sup> Therefore, vitamin D deficiency has been associated with a variety of diseases, including cancers, diabetes, systemic lupus erythematosus (SLE), rheumatoid arthritis (RA), multiple sclerosis (MS), inflammatory bowel disease (IBD), and infectious diseases.<sup>9</sup> Vitamin D plays a key role in the process of reducing inflammation and preventing the secretion of inflammatory cytokines while increasing IL-10 as a non-inflammatory cytokine.<sup>8</sup> Vitamin D also affects dendritic cells (DCs) and monocytes, and can prevent the secretion of inflammatory cytokines such as IL-1 $\beta$ , IL-6, IL-8, IL-12, and TNF- $\alpha$ .<sup>8,10</sup> In various studies, significant changes in IL-6 and TNF- $\alpha$  were observed in the serum of patients with OLP. Furthermore, these cytokines have been indicators for monitoring of lichen planus.<sup>11</sup>

According to available statistics, nearly 80% of Iranians suffer from vitamin D deficiency.<sup>12,13</sup> In addition, the anti-inflammatory effects of vitamin D and its effects on cytokines associated with autoimmune diseases have been confirmed in previous studies; however, most previous studies have been conducted on cutaneous lichen planus (CLP).<sup>14,15</sup> Few studies have evaluated the effects of vitamin D deficiency on OLP and none of them investigated the effects of vitamin D on cytokines' levels. Therefore, the present study aimed to evaluate the effect of vitamin D on the severity of pain, burning, and lesions of patients with OLP and serum levels of IL-6 and TNF- $\alpha$  before and after the treatment.

## Methods

This randomized double-blind, placebo-controlled clinical trial was conducted in patients with OLP who referred to the Department of Oral and Maxillofacial Diseases, Mashhad School of Dentistry from October 2015 to June 2016. The information of the subjects was confidential and written informed consent was obtained from all participants. The study was approved by the Ethics Committee of Mashhad School of Dentistry (registration number: IR.MUMS.SD.REC.1394.15). The research was subsequently registered on the website of the Iranian Registry of Clinical Trial (IRCT) with the registration code of IRCT20171017036835N2. The inclusion criteria for the two study groups were as follows: patients with erosive-atrophic OLP which was confirmed by clinical and histopathological criteria according to World Health Organization (WHO) modified criteria<sup>16</sup> with grade 2 to 5 based on Thongprasom Index<sup>16</sup> and with vitamin D deficiency or insufficiency [25-hydroxyvitamin D (25(OH)D) < 30 ng/ml]<sup>17</sup> were included in this study. The exclusion criteria in this study were: moderate to severe dysplasia, the use of any vitamin supplements in the past three months, serum calcium level above 10 mg/dl, serum phosphorus level less than 2.5 mg/dl, lichenoid reaction, pregnancy,

osteomalacia, primary hyperparathyroidism, severe renal-hepatic dysfunction, chronic inflammatory disease, sarcoidosis, history of malabsorption or chronic pancreatitis, allergic reaction to vitamin D supplements, and use of barbiturates and phenytoin.<sup>18,19</sup>

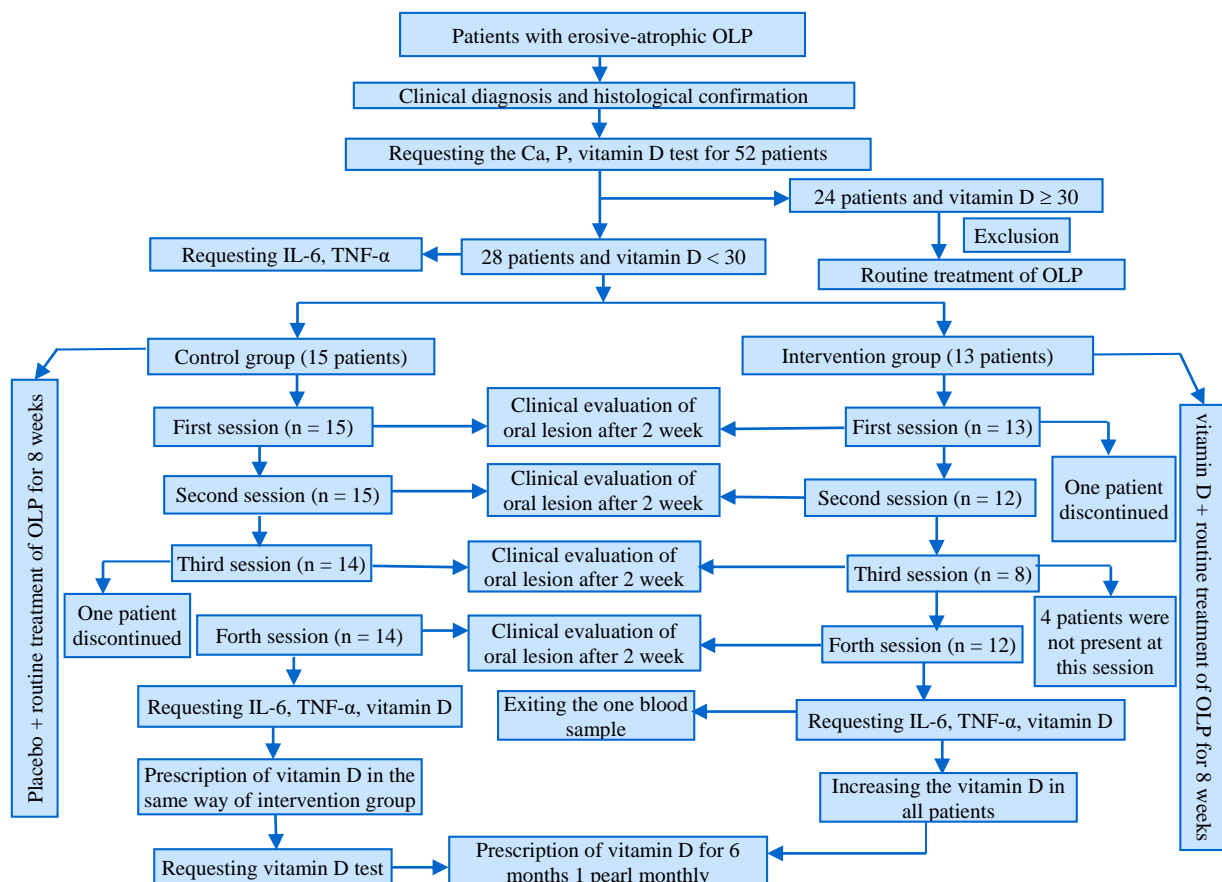
In the current study, 52 patients with erosive-atrophic OLP presented to the reference laboratory and 5 cc of the blood sample was used to assess the calcium, phosphorus (by a conventional biochemical method) and vitamin D by enzyme-linked immunosorbent assay (ELISA) method, and 1 cc of the sample was stored at -20 °C for later detection of TNF- $\alpha$  and IL-6 (Kit-Diaclone, France, by ELISA method). Finally, 28 patients with OLP with vitamin D deficiency or insufficiency and other eligibility criteria were included in the trial. The demographic data and clinical characteristics of all patients, including age, gender, lesion site, and medical background were collected in the

study checklists. The severity of burning and pain on the basis of the visual analog scale (VAS: 0-10) and the severity of lesions measured by Thongprasom Index were recorded in the first and each follow-up session. The patients were evaluated every two weeks up to two months (Table 1).

**Table 1.** Thongprasom Index

Score	Clinical signs
0	No lesion, normal mucosa
1	Mild white striae, no erythematous area
2	White striae with atrophic area less than 1 cm <sup>2</sup>
3	White striae with atrophic area more than 1 cm <sup>2</sup>
4	White striae with ulcerative area less than 1 cm <sup>2</sup>
5	White striae with ulcerative area more than 1 cm <sup>2</sup>

*Intervention and randomization:* Patients were randomly divided into two groups, the intervention group (n = 13) and the control group (n = 15) by using the sealed envelope method. Figure 1 illustrates the flow diagram of the study procedure.



**Figure 1.** Flow diagram of the study procedure (OLP: Oral lichen planus; IL-6: Interleukin 6; TNF- $\alpha$ : Tumor necrosis factor alpha)

The pearl of vitamin D3 50000 IU (manufactured by Zahravi Pharmaceutical Company, East Azerbaijan, Iran) and identical placebo tablets (containing lactose) were pre-packaged by a pharmacologist in identical capsules in terms of color, size, odor, and taste. Vitamin D and placebo capsules were administered for the intervention group and placebo group once a week for 8 weeks. The clinicians and patients were blind to the type of therapy prescribed. Additionally, the routine treatment of lichen planus was performed for both groups (dexamethasone mouthwash 0.5 mg/ml and Nystatin mouthwash 100000 U 2-3 times/day). After 8 weeks, the results were compared between both groups and among members of each group. Vitamin D status, TNF- $\alpha$ , and IL-6 levels were assessed in the two groups. Then, all patients were referred to the endocrinologist for follow-up treatments.

The data analysis was carried out using SPSS statistical software (version 16, SPSS Inc., Chicago, IL, USA). Kolmogorov-Smirnov statistical test was used to determine the normal distribution of quantitative data. All quantitative variables in the two groups had a normal distribution. Therefore, to compare these variables in the two groups, independent t-test was used. In addition, chi-square test, Mann-Whitney U-test, and repeated measures test were employed to compare other variables. Pearson correlation coefficient was used to evaluate the potential relationship between the normal variables. The P-value < 0.05 was considered as significant.

## Results

In the current study, the mean age  $\pm$  standard deviation (SD) of all patients with OLP was  $48.86 \pm 12.77$  years. The mean age of the

intervention and control group was  $44.85 \pm 11.88$  (22 to 64 years) and  $52.33 \pm 12.10$  (28 to 70 years), respectively. Moreover, the majority of patients in both groups were women. Demographic information of all patients is presented in table 2. At the beginning of the study, the two groups were matched in terms of age, sex, severity and burning of lesions, and mean of vitamin D, IL-6, and TNF- $\alpha$  levels ( $P > 0.05$ ) (Tables 2-5).

**Severity of lesions and burning:** There was a significant difference between the two groups for the mean  $\pm$  SD of burning and pain of the lesions based on the VAS score, only in the first and the second sessions ( $P = 0.014$  and  $P = 0.002$ , respectively) (Table 4). In addition, regardless of the sessions and groups, a significant decreasing trend was observed by using repeated measures test ( $P < 0.001$ ); however, a decreasing trend was more remarkable in the intervention group (Figure 2a). After the treatment, the severity of lesions was significantly reduced in the intervention group ( $P = 0.043$ ) but not in the control group. In addition, a remarkable difference was observed between the two groups for the severity of the lesions only in the second session, based on Thongprasom Index ( $P = 0.040$ ) (Table 5), which showed a significant decreasing trend only in the intervention group when compared with pre-treatment conditions ( $P < 0.013$ ); however, these changes were not significant in the control group ( $P = 0.262$ ) (Figure 2b).

**Cytokines:** After the treatment, the mean of TNF- $\alpha$  in the intervention group significantly decreased compared with the control group ( $P < 0.001$ ). Moreover, there was no significant difference between the mean of TNF- $\alpha$  in the two groups after the treatment ( $P = 0.658$ ) (Table 3 and Figure 2c).

**Table 2.** Demographic data of the subjects

Characteristics	Intervention	Control	P
Sex [n (%)]			0.150*
Female	11 (84.6)	9 (60.0)	
Male	2 (15.4)	6 (40.0)	
Smoker [n (%)]	0 (0.0)	3 (20.0)	0.088**
Systemic disorders [n (%)]	4 (30.8)	7 (46.7)	0.390*
Taking other medication [n (%)]	9 (69.2)	9 (60.0)	0.611*
Age (mean $\pm$ SD)	$44.85 \pm 11.88$	$52.33 \pm 12.11$	0.112***

\*Chi-square test, \*\*Fisher's exact test, \*\*\*Independent t-test, SD: Standard deviation

**Table 3.** Comparison of calcium, phosphorus, vitamin D, interleukin 6 (IL-6), and tumor necrosis factor alpha (TNF- $\alpha$ ) in the intervention and control groups

Variable	Intervention	Control	P*
Calcium (mean $\pm$ SD)	9.76 $\pm$ 0.51	9.72 $\pm$ 0.40	0.813
Phosphorus (mean $\pm$ SD)	3.80 $\pm$ 0.71	3.69 $\pm$ 0.65	0.664
Vitamin D (ng/mL) (mean $\pm$ SD)			
Before treatment	16.20 $\pm$ 7.89	16.91 $\pm$ 4.51	0.768
After treatment	43.20 $\pm$ 8.78	18.69 $\pm$ 9.56	< 0.001
P**	< 0.001	0.107	
IL-6 (mg/dl) (mean $\pm$ SD)			
Before treatment	3.15 $\pm$ 1.51	2.51 $\pm$ 1.37	0.280
After treatment	1.34 $\pm$ 1.52	1.09 $\pm$ 1.23	0.653
P**	0.005	0.014	
TNF- $\alpha$ (mg/dl) (mean $\pm$ SD)			
Before treatment	2.34 $\pm$ 1.38	1.30 $\pm$ 1.13	0.051
After treatment	1.89 $\pm$ 2.23	2.24 $\pm$ 1.67	0.658
P**	< 0.001	0.261	

\*Independent t-test, \*\*Paired t-test

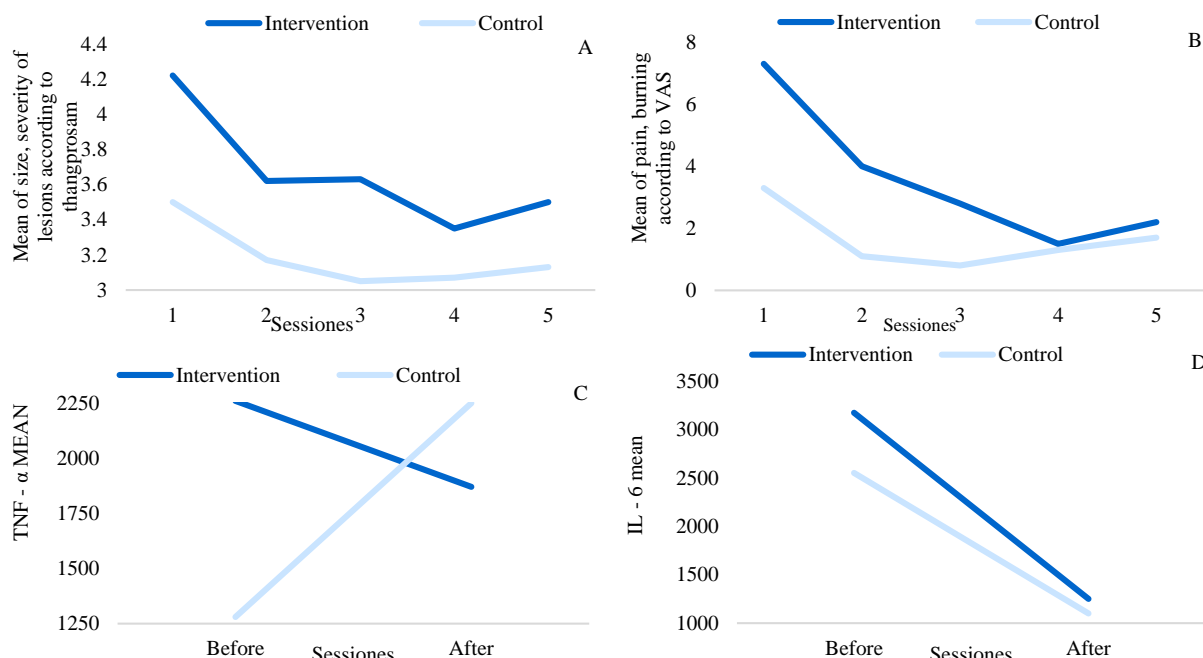
IL-6: Interleukin 6; TNF- $\alpha$ : Tumor necrosis factor alpha; SD: Standard deviation**Table 4.** Comparison of pain and burning in different treatment sessions between the two groups according to the visual analog scale (VAS) score

Characteristics	Intervention	Control	P*
Before treatment	7.38 $\pm$ 3.25	3.36 $\pm$ 3.41	0.062
First session	4.13 $\pm$ 2.64	1.21 $\pm$ 1.67	0.014
Second session	2.75 $\pm$ 2.43	0.93 $\pm$ 1.33	0.002
Third session	1.63 $\pm$ 1.69	1.29 $\pm$ 2.16	0.567
Fourth session	2.13 $\pm$ 2.33	1.64 $\pm$ 2.31	0.127
P**	< 0.001	0.019	

Data are presented as mean  $\pm$  standard deviation (SD)

\*Paired t-test, \*\*Repeated measures test

The mean of IL-6 in the intervention and control groups significantly decreased after the treatment compared to pre-treatment conditions ( $P = 0.005$  and  $P = 0.014$ , respectively). The changes between the two groups were not significant ( $P = 0.653$ ) (Table 3 and Figure 2d). Pearson correlation coefficient showed a direct correlation between IL-6 and TNF- $\alpha$  in the intervention group ( $P = 0.002$ ) and between VAS and the severity of lesions in the control group ( $P = 0.005$ ).

**Figure 2.** A) Changes in the severity of lesions based on the Thongprasom Index in different sessions; B) Changes in the severity of pain and burning according to visual analog scale (VAS) score at different sessions; C) Tumor necrosis factor alpha (TNF- $\alpha$ ) mean changes before and after the treatment; D) Interleukin 6 (IL-6) mean levels before and after the treatment

**Table 5.** Comparison of the severity of the lesions in different treatment sessions between the two groups based on Thongprasom Index

Group sessions	Intervention	Control	P*
	Mean ± SD	Mean ± SD	
Before treatment	4.25 ± 0.89	3.50 ± 0.94	0.056
First session	3.63 ± 0.92	3.14 ± 0.54	0.142
Second session	3.63 ± 0.74	3.07 ± 0.92	0.040
Third session	3.38 ± 0.52	3.07 ± 0.62	0.298
Fourth session	3.50 ± 0.93	3.14 ± 0.86	0.182
P**	0.043	0.262	

\*Paired t-test; \*\*Repeated measures test  
SD: Standard deviation

No significant relationship was found between other variables including VAS and the severity of lesions and cytokine and vitamin D levels ( $P > 0.05$ ). In addition, no drug-related side effect was observed in the current study.

## Discussion

Lichen planus is an immune-mediated disease and the presence of inflammatory cytokines plays a significant role in its development and progression. In our study, oral administration of vitamin D reduced the severity of lesions based on Thongprasom Index and inflammatory cytokines. The pathogenesis of inflammatory mechanisms in OLP is not clarified; however, immunologic reactions such as immune cells, inflammatory cytokines, and inappropriate oxidation are the main causative factors.<sup>20</sup> The keratinocytes and mononuclear cells, which accumulate in the tissue, produce a network of cytokines such as GM-CSF, IL-6, TNF- $\alpha$ , and other inflammatory cytokines, which are effective in inflammation process and play a major role in the development of OLP.<sup>5,21</sup>

Vitamin D insufficiency is increasing among the general population due to the greater use of sunscreen, more indoor activities, and greater skin coverage with clothing. Active form of vitamin D, 1,25-dihydroxyvitamin D [1,25(OH)<sub>2</sub>D<sub>3</sub>], affects wide-range biological activities.<sup>3</sup> The effects of vitamin D on different organs, especially the immune system, have been proven.<sup>3,22</sup> This vitamin inhibits the

proliferation of B cells and T cells and drives the shift of T cells from Th1 to Th2 cells.<sup>10</sup> Moreover, vitamin D mainly affects the inflammatory process through the inhibition of nuclear factor kappa B (NF- $\kappa$ B) and reduction of Th17.<sup>10,23</sup> It also increases the level of IL-10, an anti-inflammatory cytokine, and inhibits the production of inflammatory cytokines such as IL-1, IL-6, IL-8, IL-12, and TNF- $\alpha$  in monocytes.<sup>10,24</sup> Furthermore, the physiological functions of 1,25(OH)<sub>2</sub>D<sub>3</sub> are regulated by vitamin D receptors (VDRs), which are significantly expressed in various types of cells.<sup>25</sup> Some researchers believe that OLP development is associated with polymorphisms of the VDR gene.<sup>26</sup>

Du et al. assessed vitamin D/VDR in biopsies of patients with OLP and HaCat cells in vitro.<sup>3</sup> It was shown that the deficiency of VDR in the biopsies of patients with OLP was associated with activated Th1-mediated inflammatory response. The level of serum 25(OH)D of patients with OLP was reduced consistently. In a cell culture model, the production of proinflammatory factors, induced by lipopolysaccharide (LPS) in keratinocyte HaCat cells, was decreased by 25(OH)<sub>2</sub>D<sub>3</sub>. The researchers suggested that the emergence of OLP in the patients might be associated with a reduction of local VDR and global 25(OH)D. It seems that the main cause of Th1-dominated diseases is insufficiency of vitamin D or VDR.<sup>3</sup> Erosive-atrophic OLP is usually associated with some pain and burning and needs to be treated. No definitive treatment for OLP has ever been found.<sup>27,28</sup> Most treatments have had a role in reducing signs and symptoms such as pain and burning.<sup>28,29</sup> The main and most common treatment for this disease is the use of topical and sometimes systemic corticosteroids, leading to severe side effects in patients such as oral candidiasis, increased mucosal fragility, and reduction of wound healing.<sup>30,31</sup> Therefore, the use of other drugs can help to effectively respond and reduce complications, especially in refractory OLP.<sup>29</sup>

To the best of our knowledge, few studies

investigated the effects of vitamin D on erosive-atrophic OLP. In Seif et al. study, vitamin D deficiency or insufficiency was observed in a high percentage of patients with OLP; however, the difference was not significant between OLP and healthy subjects.<sup>32</sup> The current research was conducted on the patients with OLP to evaluate clinical lesions and cytokines probably associated with this disease, which could be effective in the assessment of disease activity and the response to the treatment. The level of IL-6 in each group (in particular the intervention group) decreased significantly compared to pre-treatment conditions; however, the changes between the two groups were not significant. It seems that the reduction of IL-6 in both groups could be attributed to the use of topical corticosteroid therapy.<sup>33</sup> The levels of TNF- $\alpha$  insignificantly decreased only in the intervention group at the end of the treatment compared to pre-treatment conditions. In this study, a significant correlation between IL-6 and TNF- $\alpha$  changes is shown ( $r = 0.82$ ,  $P = 0.002$ ); however, the analysis could not reveal significant relationships between other variables, including burning and the severity of lesions and cytokine and vitamin D levels.

TNF- $\alpha$  stimulates the activity of B cells to secrete IL-1 $\beta$  and IL-6. Moreover, according to the results of other studies in patients with OLP, TIMCs produce more TNF- $\alpha$  and GM-CSF than peripheral blood mononuclear cells (PBMCs), due to stimulation of IL-6. Therefore, it seems that IL-6 and TNF- $\alpha$  can affect each other.<sup>11</sup> Razi et al. treated OLP in perimenopausal women with vitamin D deficiency or insufficiency and revealed that adjunctive therapy with vitamin D caused a significant improvement in patients' signs and symptoms.<sup>34</sup> Gupta et al. showed a significant improvement in burning sensation and the severity of the lesions in patients with OLP who received vitamin D and topical steroids.<sup>35</sup> The results of our study were consistent with these results; nevertheless, different sample sizes, inclusion

criteria, and psychiatric consultation, especially in Gupta et al. study, made these studies different. Gupta et al. only prescribed vitamin D supplements for patients with OLP with severe vitamin D deficiency ( $\leq 15$  ng/ml),<sup>35</sup> while we performed intervention for patients with OLP with vitamin D deficiency or insufficiency ( $< 30$  ng/ml) and evaluated the effect of the treatment on some cytokines.

We found that the severity of lesions at the end of treatment was significantly lower only in the intervention group than pre-treatment conditions. Moreover, the severity of pain and burning in both groups was reduced after the treatment when compared to the first session. No side effects were observed in patients by using high doses of vitamin D. Indeed, vitamin D is a high-tolerance vitamin, and intoxication and side effects occur in case of high dose intake. A number of studies have assessed the effect of vitamin D analogs on CLP. Bayramgurler et al. concluded that calcipotriol could be considered as one of the treatment options for lichen planus, but it was not regarded as the first line of the treatment.<sup>15</sup> In addition, a Singaporean OLP group observed similar effects of local calcipotriol ointment and betamethasone ointment on treating CLP.<sup>14</sup> Approximately, 50% of patients in both groups were improved. It was concluded that calcipotriol and betamethasone could be equally effective in treating lichen planus.

Comparison of the present study with aforementioned studies was difficult because of different sample sizes and follow-up periods. Moreover, none of the studies had a control group, and the treatments applied in the two previous studies administered topical vitamin D analogs in CLP. The most important limitation of this study was the use of routine therapy in the placebo group because of ethical considerations. It is suggested that further studies with larger sample sizes and long-term follow-ups without use of routine therapy should be performed in the placebo group for better evaluation of improvement and recurrence of

oral lesions after vitamin D administration.

### Conclusion

Based on the results of this study, the severity of the lesions and the levels of IL-6 and TNF- $\alpha$  were reduced in the patients treated with vitamin D. It may suggest using vitamin D as an adjunct or even a substitute for treatment of OLP lesions, but further studies are needed for definitive results.

### Conflict of Interests

Authors have no conflict of interest.

### Acknowledgments

The Vice Chancellor for Research of Mashhad University of Medical Sciences is highly appreciated for supporting this research. The results described in this paper were part of a postgraduate student's thesis (No. 598).

### References

1. Aghbari SMH, Abushouk AI, Attia A, Elmarazy A, Menshawy A, Ahmed MS, et al. Malignant transformation of oral lichen planus and oral lichenoid lesions: A meta-analysis of 20095 patient data. *Oral Oncol* 2017; 68: 92-102.
2. Pakfetrat A, Javadzadeh-Bolouri A, Basir-Shabestari S, Falaki F. oral lichen planus: A retrospective study of 420 Iranian patients. *Med Oral Patol Oral Cir Bucal* 2009; 14(7): E315-E318.
3. Du J, Li R, Yu F, Yang F, Wang J, Chen Q, et al. Experimental study on 1,25(OH)<sub>2</sub> D<sub>3</sub> amelioration of oral lichen planus through regulating NF-kappaB signaling pathway. *Oral Dis* 2017; 23(6): 770-8.
4. Kalogerakou F, Albanidou-Farmaki E, Markopoulos AK, Antoniadis DZ. Detection of T cells secreting type 1 and type 2 cytokines in the peripheral blood of patients with oral lichen planus. *Hippokratia* 2008; 12(4): 230-5.
5. Yamamoto T, Osaki T, Yoneda K, Ueta E. Cytokine production by keratinocytes and mononuclear infiltrates in oral lichen planus. *J Oral Pathol Med* 1994; 23(7): 309-15.
6. Yamamoto T, Yoneda K, Ueta E, Hirota J, Osaki T. Serum cytokine levels in patients with oral mucous membrane disorders. *J Oral Pathol Med* 1991; 20(6): 275-9.
7. Feldman D, Krishnan AV, Swami S, Giovannucci E, Feldman BJ. The role of vitamin D in reducing cancer risk and progression. *Nat Rev Cancer* 2014; 14(5): 342-57.
8. Kamen DL, Tangpricha V. Vitamin D and molecular actions on the immune system: Modulation of innate and autoimmunity. *J Mol Med (Berl)* 2010; 88(5): 441-50.
9. Di Rosa M., Malaguarnera M, Nicoletti F, Malaguarnera L. Vitamin D<sub>3</sub>: A helpful immuno-modulator. *Immunology* 2011; 134(2): 123-39.
10. Aranow C. Vitamin D and the immune system. *J Investig Med* 2011; 59(6): 881-6.
11. Lu R, Zhang J, Sun W, Du G, Zhou G. Inflammation-related cytokines in oral lichen planus: An overview. *J Oral Pathol Med* 2015; 44(1): 1-14.
12. Hashemipour S, Larijani B, Adibi H, Javadi E, Sedaghat M, Pajouhi M, et al. Vitamin D deficiency and causative factors in the population of Tehran. *BMC Public Health* 2004; 4: 38.
13. Moradzadeh K, Larijani B, Keshtkar AA, Hossein-Nezhad A, Rajabian R, Nabipour I. Normative values of vitamin D among Iranian population: A population based study. *International Journal of Osteoporosis and Metabolic Disorders* 2008; 1: 8-15. [In Persian].
14. Theng CT, Tan SH, Goh CL, Suresh S, Wong HB, Machin D. A randomized controlled trial to compare calcipotriol with betamethasone valerate for the treatment of cutaneous lichen planus. *J Dermatolog Treat* 2004; 15(3): 141-5.
15. Bayramgurler D, Apaydin R, Bilen N. Limited benefit of topical calcipotriol in lichen planus treatment: A preliminary study. *J Dermatolog Treat* 2002; 13(3): 129-32.
16. Thongprasom K, Luangjarmekorn L, Sererat T, Taweasap W. Relative efficacy of fluocinolone acetonide compared with triamcinolone acetonide in treatment of oral lichen planus. *J Oral Pathol Med* 1992; 21(10): 456-8.
17. Hashemi SM, Mokhtari SM, Sadeghi M, Foroozan R, Safari M. Effect of vitamin D therapy on endothelial function in ischemic heart disease female patients with vitamin D deficiency or insufficiency: A primary report. *ARYA Atheroscler* 2015; 11(1): 54-9.
18. Robien K, Oppeneer SJ, Kelly JA, Hamilton-Reeves JM. Drug-vitamin D interactions: A systematic review of the literature. *Nutr Clin Pract* 2013; 28(2): 194-208.
19. Amirchaghmaghi M, Pakfetrat A, Delavarian Z, Ghalavani H, Ghazi A. Evaluation of the efficacy of curcumin in the treatment of oral lichen planus: A randomized controlled trial. *J Clin Diagn Res* 2016; 10(5): ZC134-ZC137.
20. Parashar P. Oral lichen planus. *Otolaryngol Clin North Am* 2011; 44(1): 89-107, vi.
21. Brant JM, Vasconcelos AC, Rodrigues LV. Role of apoptosis in erosive and reticular oral lichen planus exhibiting variable epithelial thickness. *Braz Dent J* 2008; 19(3): 179-85.
22. Holick MF. Vitamin D deficiency. *N Engl J Med* 2007; 357(3): 266-81.



23. Wang H, Zhang D, Han Q, Zhao X, Zeng X, Xu Y, et al. Role of distinct CD4(+) T helper subset in pathogenesis of oral lichen planus. *J Oral Pathol Med* 2016; 45(6): 385-93.
24. Hewison M. Vitamin D and the immune system: New perspectives on an old theme. *Endocrinol Metab Clin North Am* 2010; 39(2): 365-79, table.
25. Holick MF. Vitamin D and bone health. *J Nutr* 1996; 126(4 Suppl): 1159S-64S.
26. Kujundzic B, Zeljic K, Supic G, Magic M, Stanimirovic D, Ilic V, et al. Association of vdr, cyp27b1, cyp24a1 and mthfr gene polymorphisms with oral lichen planus risk. *Clin Oral Investig* 2016; 20(4): 781-9.
27. Ramadas AA, Jose R, Arathy SL, Kurup S, Chandy ML, Kumar SP. Systemic absorption of 0.1% triamcinolone acetate as topical application in management of oral lichen planus. *Indian J Dent Res* 2016; 27(3): 230-5.
28. Thongprasom K, Dhanuthai K. Steroids in the treatment of lichen planus: A review. *J Oral Sci* 2008; 50(4): 377-85.
29. Sugerman PB, Savage NW. Oral lichen planus: Causes, diagnosis and management. *Aust Dent J* 2002; 47(4): 290-7.
30. Lavanya N, Jayanthi P, Rao UK, Ranganathan K. Oral lichen planus: An update on pathogenesis and treatment. *J Oral Maxillofac Pathol* 2011; 15(2): 127-32.
31. Patil S, Khandelwal S, Sinha N, Kaswan S, Rahman F, Tipu S. Treatment modalities of oral lichen planus: An update. *Journal of Oral Diagnosis* 2016; 1(1): 1.
32. Seif S, Jafari-Ashkavandi Z, Mardani M, Hamidizadeh N. Evaluation of serum vitamin D level in oral lichen planus patients. *J Mashad Dent Sch* 2018; 42(1): 58-49. [In Persian].
33. Lahiri K, Coondoo A. Topical steroid damaged/dependent face (TSDF): An entity of cutaneous pharmacodependence. *Indian J Dermatol* 2016; 61(3): 265-72.
34. Razi A, Mohiuddin S, Karim AA, Iqbal A. Vitamin D as an adjuvant therapy to cure oral lichen planus in perimenopausal women. *Pak Oral Dental* 2018; 38(4): 399.
35. Gupta J, Aggarwal A, Asadullah MD, Khan MH, Agrawal N, Khwaja KJ. Vitamin D in the treatment of oral lichen planus: A pilot clinical study. *J Indian Acad Oral Med Radiol* 2019; 31(3): 222-7.