

## Bilateral supernumerary maxillary lateral incisors: A rare case report

Somayeh Hekmatfar MSc, DDS<sup>1</sup>, Samaneh Badakhsh MSc, DDS<sup>2</sup>,  
Karim Jafari MSc, DDS<sup>3</sup>

### Case Report

#### Abstract

**BACKGROUND AND AIM:** Supernumerary tooth (ST) is considered as a developmental tooth abnormality in number that most often occurs in the anterior region of the maxilla. They may erupt or remain impacted in the alveolar bone. The impacted teeth can cause eruptional disturbances for the adjacent developing teeth.

**CASE REPORT:** A case of bilateral supplemental maxillary lateral incisors in a nonsyndromic 9-year-old boy, with no adverse effect on the adjacent teeth, is reported. Patient's medical history was non-contributory. Family history was negative for any dental abnormality.

**CONCLUSION:** Radiographic assessment of both dental arches can discover any potential problem likely to develop during the course of the child's growth. Early diagnosis is important in order to minimize the risk of complications. Formation of supplemental lateral incisors occurs less frequently, and bilateral cases are rarely found.

**KEYWORDS:** Lateral Incisors, Tooth, Supernumerary, Tooth Abnormalities, Maxilla

**Citation:** Hekmatfar S, Badakhsh S, Jafari K. **Bilateral supernumerary maxillary lateral incisors: A rare case report.** *J Oral Health Oral Epidemiol* 2015; 4(1): 46-50.

Supernumerary tooth (ST) is defined as an extra tooth in addition to the normal series of dentition. They may or may not be associated with a syndrome.<sup>1</sup> ST may present unilaterally, bilaterally, single or multiple and may be seen in either maxilla or mandible. The etiology of this phenomenon is not clearly understood. The localized hyperactivity of the developing dental lamina is the most accepted theory suggesting a local, independent proliferation in dental lamina. Furthermore, some studies have demonstrated that the incidence of the ST in the first-degree relatives is higher than the general population, although, this phenomenon does not follow a simple Mendelian pattern.<sup>2</sup>

They are more common in permanent dentition compared to primary dentition

(0.1-3.8%)<sup>3</sup> versus (0.3-0.8%).<sup>4</sup> The less prevalence of ST in primary dentition is likely due to exfoliation or extraction of them and therefore they are rarely reported.<sup>3</sup> Males are affected approximately twice as often as females while there is no gender tendency in primary ST.<sup>4</sup> However, Wedrychowska-Szulc and Janiszewska-Olszowska stated that supplemental lateral incisors occur with the same frequency in both sexes.<sup>5</sup> Although, both jaws are disposed, the most frequent region for ST presence is the anterior region of the maxilla. ST in the maxilla is 8 times more than those develop in the lower jaw.<sup>6</sup> Mesiodens is the most common ST that is an extra tooth usually small and conical in shape locating between the maxillary central incisors.<sup>1</sup>

On the basis of the morphology, S-Teeth are classified into two types:<sup>2</sup>

1- Assistant Professor, Department of Pediatric Dentistry, School of Dentistry, Ardabil University of Medical Sciences, Ardabil, Iran

2- Assistant Professor, Department of Pediatric Dentistry, School of Dentistry, Tehran University of Medical Sciences, Tehran, Iran

3- Assistant Professor, Department of Prosthodontics, School of Dentistry, Ardabil University of Medical Sciences, Ardabil, Iran

Correspondence to: Samaneh Badakhsh, MSc, DDS

Email: drbadakhsh@yahoo.com

1- Supplemental: This type of ST is closely similar to normal tooth in shape and size and is found at the end of the tooth series. The most common supplementary ST is maxillary permanent lateral incisor. Furthermore, most of the supernumerary teeth reported in the primary dentition are of this type.

2- Rudimentary: This type may be smaller in size or abnormal in shape. They may be seen as the following forms: conical, tuberculate, and molariform. Conical supernumerary teeth are small and peg-shaped most often occurs as mesiodens locating between the maxillary central incisors. Tuberculate ones are defined as a larger, barrel-shaped ST compared to the conical ones. They are usually located at the palatal aspect of the central incisors and may rarely erupt. Furthermore, despite odontoma is a hamartoma with the origin of the odontogenic tissues, some studies listed that as another category of ST. However, it is not accepted by general.<sup>2</sup>

The supernumerary teeth may erupt or remain impacted, both cases may lead to clinical problems. In general, these teeth might be responsible for the following problems: Over-retained primary teeth, delayed eruption or Impaction of the permanent teeth, ectopic eruptions, tooth displacements or rotations, crowding due to the eruption of the ST, pathological features such as development of odontogenic cysts (i.e., follicular cyst, dentigerous cyst), damage to the adjacent teeth such as resorption of the roots (extremely rare) or loss of vitality, abnormal diastema. Root resorption of the adjacent permanent teeth is the most important and frequent complication that may occur in this patient if the teeth are left untreated.<sup>4</sup>

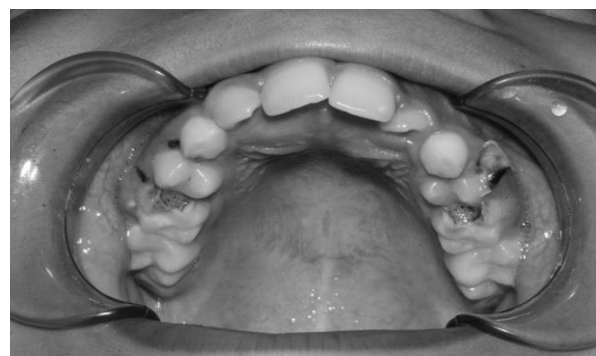
The case reported in this article has bilateral supplemental maxillary lateral incisors without any local eruption disorder or malocclusion.

### Case Report

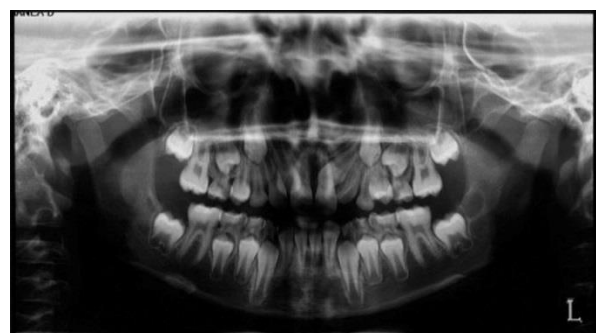A 9-year-old boy was referred to Department

of Pediatric Dentistry of Shiraz University of Medical Sciences, Iran, with the chief complaint of dental caries. The patient's medical history was non-contributory; there was no previous history of trauma to the teeth or jaws and no abnormality in extra-oral examination. In intraoral examination, the patient was in the mixed dentition stage, with deep carious lesions in the primary molars, and just a slight swelling was detected on the palatal side of the maxillary incisors (Figure 1).

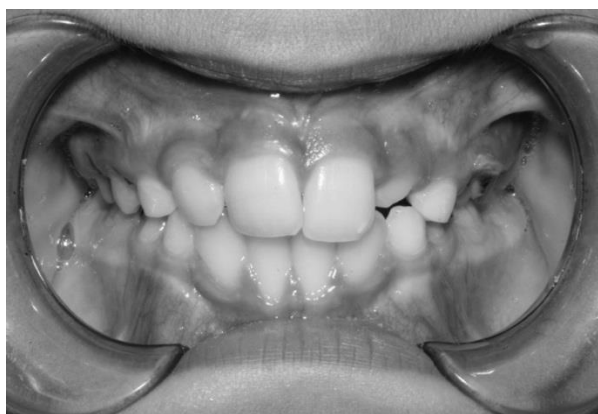Posterior bitewing radiograph was made for evaluation of the caries lesion. In addition, panoramic radiograph was required for detecting developmental disorders. Panoramic survey of the teeth and jaws revealed un-erupted bilateral supplemental permanent maxillary lateral incisors. It seems that the morphology and size of the supernumerary teeth were normal, and they were located between the erupted central and lateral incisors (Figure 2). Interestingly, no disturbances were seen in the eruption of the adjacent teeth (Figure 3).



**Figure 1.** A slight swallow on the palatal side presented



**Figure 2.** Panoramic view



**Figure 3.** No disturbances in the eruption of the adjacent teeth were seen

Parents and siblings of the patient were also examined, and no history of congenital dental anomalies or syndromes was observed. The parents were informed of this anomaly and the potential future complications. The patient was referred to the oral surgeon for definitive treatment. Unfortunately, due to economic issues, parents did not accept any treatment.

### Discussion

Supplemental supernumerary teeth have the typical anatomy of teeth.<sup>2</sup> According to the studies, the formation of supplemental lateral incisors occurs rarely, and bilateral cases are rarer ones. Based on the authors' search, only five bilateral cases have been reported in the literature till date (Table 1).<sup>7-11</sup> Furthermore, this is the first case report among Iranian population.

However, the etiology is still uncertain; it has been suggested that inheritance and environmental factors should be considered as possible reasons.<sup>2</sup>

There are a few syndromes or disorders associated with multiple supernumerary teeth. The most common ones are: cleft lip and palate, cleidocranial dysostosis, Gardner's syndrome, and chondroectodermal dysplasia.<sup>1</sup> However, the patient presented here did not have any of the mentioned syndromes.

Most of the supernumerary teeth identified remain un-erupted and are associated with a variety of clinical problems, such as failure or delayed eruption of the adjacent tooth, displacement or rotation, esthetic disturbances, diastema, root resorption of the surrounding teeth, dentigerous cyst, and malformation of the adjacent teeth like dilacerations.<sup>4</sup>

Early diagnosis is important in order to minimize the risk of complications resulting from supernumerary teeth and can prevent the pediatric patient from experiencing malocclusion or other developmental disturbances. Radiographic assessment of both dental arches can discover any potential problems likely to develop during the course of the child's growth. In the present case, however, the supplemental teeth are impacted, and the patient did not display any sign of eruption disturbances, according to the panoramic radiography.

**Table 1.** Nonsyndromic bilateral maxillary lateral supernumerary teeth reported till date

Study	Age (year)/Gender	Country	Primary/permanent tooth	Patient's chief complaint	Status of the supernumerary teeth
Singla and Negi <sup>7</sup>	17/Female	India	Permanent	Dental irregularity	Erupted
Nagpal et al. <sup>8</sup>	21/Female	India	Permanent	Pain in the lower jaw (non-related reason)	Erupted
Bhullar et al. <sup>9</sup>	14/Female	India	Permanent	Spacing between the front teeth	Erupted
Sharma et al. <sup>10</sup>	8/Male	India	Permanent	Dental irregularity	Un-erupted
Yildirim and Bayrak <sup>11</sup>	8/Male	Turkey	Both primary and permanent	Dental caries	Primary: not exfoliated Permanent: Un-erupted

Decision to make radiographs was based on a thorough evaluation and examination of the patient. The American Academy of Pediatric Dentistry (AAPD) emphasizes the importance of performing a complete examination before making a diagnosis and developing a treatment plan. The use of radiographic images can provide early diagnosis of all potential problems that may sometimes be undiscovered in clinical examination. AAPD suggested that diagnostic radiography should be requested for children to evaluate the presence of interproximal caries, developmental anomalies, and pathogenic conditions of the jaws. Frequency of making radiographs is determined by the child's history, clinical finding, and susceptibility to oral disease.<sup>6</sup>

There is also a correlation between supernumerary and presence of macrodontia. It is shown that the teeth in individuals with extra teeth have a tendency to be larger especially in the mesiodistal dimension. These findings suggest that the number and size of the tooth anomalies may have similar etiology.<sup>10,12</sup> However, in the case presented here, the other erupted teeth were normal in shape and size. If ST is identified through radiographic assessment, the decision whether to remove surgically or leave the teeth untreated or be under observation should be made.

Clinical findings have shown that most

supernumerary permanent teeth remain un-erupted. In order to minimizing the possible complications, extraction of the ST is recommended. There are two different approaches for removal of the ST. The immediate one is early intervention soon after the initial diagnosis, and the delayed approach recommends extraction after apical closure of the adjacent central and lateral incisors. If not interfering with the development or eruption of surrounding teeth, it is better to postpone the surgical procedure to another time especially in the cases with the possibility of the eruption of the extra tooth. The teeth should be kept under observation until the apical maturation of the adjacent teeth occurs.

In this patient, all the anterior incisors erupted in normal position, and un-erupted bilateral supplemental lateral incisors were symptomless.

In conclusion, before the diagnosis and developing a treatment plan, dentists have to evaluate the whole oral cavity for determination of any probable unknown conditions. Radiograph views may complete the clinical examination in which allows the practitioner to identify patients developmental anomalies of teeth and pathologic conditions of the hard and soft tissues, jaw and associated structures.

### Conflict of Interests

Authors have no conflict of interest.

### References

1. Mali S, Rashmiraj Karjodkar F, Sontakke S, Sansare K. Supernumerary teeth in non-syndromic patients. *Imaging Sci Dent* 2012; 42(1): 41-5.
2. Schmuckli R, Lipowsky C, Peltomaki T. Prevalence and morphology of supernumerary teeth in the population of a Swiss community. *Short communication. Schweiz Monatsschr Zahnmed* 2010; 120(11): 987-93.
3. Schuurs AH, van Loveren C. Double teeth: review of the literature. *ASDC J Dent Child* 2000; 67(5): 313-25.
4. Ditto D, Akhila R. Management of multiple impacted supernumerary teeth in a non-syndromic patient using Cone Beam CT. *Dentistry* 2014; 4: 2.
5. Wedrychowska-Szulc B, Janiszewska-Olszowska J. The supernumerary lateral incisors--morphology and concomitant abnormalities. *Ann Acad Med Stetin* 2007; 53(3): 107-12.
6. McDonald RE, Avery DR, Dean JA. *Dentistry for the child and adolescent*. 9<sup>th</sup> ed. London, UK: Elsevier Health Sciences; 2010.
7. Singla A, Negi A. A Case with bilateral supplemental maxillary lateral incisors. *Indian Journal of Dental Sciences* 2011; 2(1): 1-4.
8. Nagpal A, Hans MK, Shetty S, Kaur N, Kumar S. Non-syndromic bilateral supplemental maxillary lateral incisors: a

- rare case. *J Clin Diagn Res* 2013; 7(8): 1812-3.
9. Bhullar MK, Uppal AS, Kochhar GK, Singh R. Bilateral supplemental permanent maxillary lateral incisors in a non-syndromic patient. *BMJ Case Rep* 2014; 2014.
  10. Sharma A, Kirtaniya BC, Gupta K, Pathania Jaj V. Bilateral supplemental maxillary lateral incisors- a rare case report. *Indian Journal of Dental Sciences* 2014; 6(3): 68.
  11. Yildirim G, Bayrak S. Early diagnosis of bilateral supplemental primary and permanent maxillary lateral incisors: a case report. *Eur J Dent* 2011; 5(2): 215-9.
  12. Brook AH, Griffin RC, Smith RN, Townsend GC, Kaur G, Davis GR, et al. Tooth size patterns in patients with hypodontia and supernumerary teeth. *Arch Oral Biol* 2009; 54(Suppl 1): S63-S70.