

## Repair of a furcation perforation with mineral trioxide aggregate: A case report with 6 year follow-ups

Nahid Mohammadzadeh-Akhlaji DDS, MS<sup>1</sup>, Ehsan Esnaashari DDS, MS<sup>2</sup>

### Case Report

#### Abstract

**BACKGROUND AND AIM:** One of the most common reasons for the failure of endodontic treatment is root perforation. Perforations might occur due to carious lesions, tooth resorption or they might be iatrogenic during endodontic treatment or in most cases they might occur during post space preparation.

**CASE REPORT:** A 31-year-old female patient presented with a complaint of chronic pain on tooth #30 during last 6 months and sensitive to bite since a few days ago. There was a mild swelling on the gingival tissue in the furcation area in the intraoral examination, with a narrow strip-shaped pocket measuring 3 mm in depth. Radiographic examination revealed an incomplete root canal treatment of the tooth. A prefabricated post had been placed in the distal root, with an incorrect path toward the furcation area. There was a small radiolucency in the furcation area and a pronounced radiolucency around the mesial root of the tooth. After removal of the post, hemorrhage was observed in the furcation area. The diameter of the perforation was approximately 1 mm. The perforated area was sealed with Pro Root mineral trioxide aggregate (MTA). In the next session when setting of MTA was evaluated and confirmed, retreatment of the tooth was done. After 6 months, no swelling or sensitivity was observed and after 6 year follow-ups radiographic examination revealed that the lesion had almost resolved.

**CONCLUSION:** In the present case, the lesion of furcation perforation was small in size, but the time interval between the occurrence of perforation and the repair procedure was long, success was achieved due to the control of the aseptic conditions, control of hemorrhage and proper placement of the repair material, which was confirmed in the 6 year follow-ups.

**KEYWORDS:** Furcal Perforation, Mineral Trioxide Aggregate, Delay Perforation Rapiet

**Citation:** Mohammadzadeh-Akhlaji N, Esnaashari E. **Repair of a furcation perforation with mineral trioxide aggregate: A case report with 6 year follow-ups.** J Oral Health Oral Epidemiol 2015; 4(2): 102-6.

One of the most common reasons for the failure of endodontic treatment is root perforation. Perforations might occur due to carious lesions, tooth resorption or they might be iatrogenic during endodontic treatment or in most cases they might occur during post space preparation.<sup>1</sup> A large number of factors influence the prognosis of perforated teeth, including the duration of the presence of perforation, perforation size and its location relative to the crest of the alveolar bone, presence of a periapical lesion and the time interval between the occurrence of

perforation and the repair procedure.<sup>2</sup>

Therefore, the perforated tooth will have a better prognosis if the perforation is small, is more apical to the alveolar crest and is repaired as soon as possible. In addition, strip perforations have the worst prognosis due to lack of access to the site, close proximity with the alveolar bone and a large size.<sup>3</sup>

A wide variety of materials are used for the repair of perforations, including amalgam, zinc-oxide eugenol (ZOE), ionomer restorative materials, resin-modified glass-ionomers (Gristore),<sup>4</sup> calcium enriched mixture cement<sup>5</sup> and mineral trioxide aggregate (MTA).<sup>6</sup> MTA

1- Associate Professor, Department of Endodontics, Islamic Azad University, Dental Branch, Tehran, Iran

2- Assistant Professor, Department of Endodontics, Islamic Azad University, Dental Branch, Tehran, Iran

Correspondence to: Ehsan Esnaashari, DDS, MS

Email: ehsan\_dmd@yahoo.com

was introduced by Arens and Torabinejad as an appropriate perforation repair material.<sup>2</sup> It has exhibited less leakage compared to the materials mentioned above in various leakage studies, including fluid filtration, dye leakage, and bacterial leakage studies. It can induce cementogenesis and osteogenesis at perforation site, leading to the regeneration of periodontium.<sup>6</sup> In addition, in cases not directly accessible for perforation repair and when it is not possible to control hemorrhage, MTA can serve both as a physical barrier and as a repair material. MTA is commonly the material of choice to repair root perforations.<sup>7,8</sup>

The aim of this article is to report a case of root perforation in the function area due to improper placement of a post, its repair, and its 6 year follow-ups.

### Case Report

A 31-year-old female patient presented with a complaint of chronic pain on tooth #30 during last 6 months and sensitive to bite since a few days ago. The patient was systemically healthy, with no swelling in the facial area and enlargement of lymph nodes on extraoral examinations and patient could not remember the time of previous treatment. There was a mild swelling on the gingival tissue in the buccal furcation area in the intraoral examination, with a narrow strip-shaped pocket measuring 3 mm in depth; probing was normal on other tooth surfaces. The tooth was sensitive to percussion and painful on palpation. In addition, the tooth had an ill-fitting crown.

Radiographic examination revealed an incomplete root canal treatment of the tooth (Figure 1). A prefabricated post had been placed in the distal root, with an incorrect path toward the furcation area. In addition, a silver cone was located in the mesiolingual canal and a broken instrument in mesiobuccal canal. There was a small radiolucency in the furcation area and a pronounced radiolucency around the mesial root of the tooth.

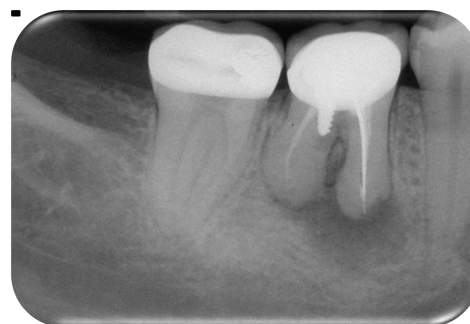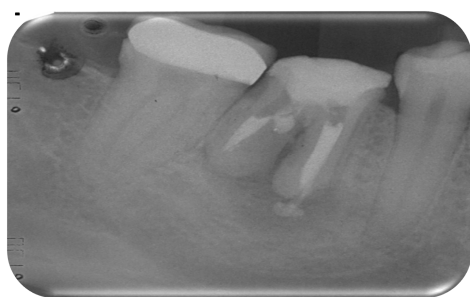


Figure 1. Pre-treatment X-ray

During the first session, the tooth prosthetic crown was removed. After isolation of the tooth and removal of the amalgam from the tooth crown and the pulp chamber space, the post was vibrated by an ultrasonic device (EMS- Piezon Airflow, Switzerland) for 5 min and removed from the root canal space by a hemostat. After removal of the post, hemorrhage was observed in the furcation area, which was controlled by a cotton pellet impregnated with 2.5% sodium hypochlorite for 30 s. The diameter of the perforation was approximately 1 mm. The perforated area was sealed with Pro Root MTA (Dentsply Maillefer, Ballaigues, Switzerland) using messing gun (Dentsply Maillefer, Ballaigues, Switzerland) and compressed lightly with a small wet cotton pellet. Temporary dressing was placed in the area after placement of a piece of the wet cotton pellet. The patient was cautioned that there might be pain and swelling in the area. Immediately after the perforation repair procedure, two 400 mg ibuprofen tablets were prescribed, and the patient was advised to take 1 tablet very 4-6 h in case of pain. In order to control the possible swelling the patient was instructed to take amoxicillin if any swelling accrues in the days after the treatment.

During the second session, recovery of gingival inflammation was observed but the tooth was still painful and sensitive to percussion. After placement of a rubber dam and removal of the temporary dressing, setting of MTA was evaluated and confirmed. Subsequently, the silver cone and

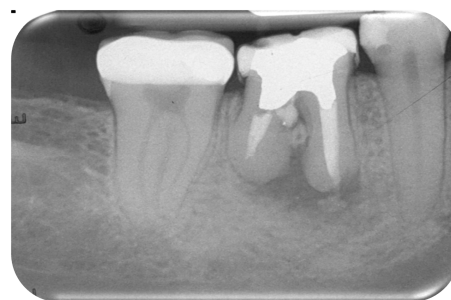broken instrument were removed from the mesial canals using a Steiglitz forceps (Pulpdent Corporation Watertown, MA, USA). Gutta-percha was removed from the coronal thirds of the canals using #4 Gates-Glidden drills (Dentsply, Tulsa Dental, Tulsa, Ok, USA) and chloroform (Merck, Darmstadt, Germany) and K-Flexofiles (Dentsply Maillefer, Ballaigues, Switzerland) #35 to #20 from the apical thirds of the canals. An attempt was made to establish apical patency using a #10 file. Patency was not established in the distal root canal (Figure 2). Working length (WL) was determined by an apex locator (J. Morita, Kyoto, Japan) and radiographic examination. The canals were debrided up to Flexofile #20. Debridement was completed by ProTaper rotary files (Dentsply Maillefer, Ballaigues, Switzerland) up to #F2 along with 1% sodium hypochlorite as an irrigation solution. The patency of mesial canals and WL of the distal canal were ensured using a #10 file between rotary files. After each file during canal preparation, 2 ml of 1% sodium hypochlorite was used for irrigation. After debridement of the canals, calcium hydroxide (Merck, Darmstadt, Germany) dressing was placed in each root canal using a #30 K-file and packed using #25 and #30 pluggers.



**Figure 2.** During treatment X-ray

During the third session after a month, when the patient had no sign and symptom and the canals were once again irrigated with 1% sodium hypochlorite after isolation and calcium hydroxide was removed with a #30 K-file. Final canal irrigation was carried out

using 2 ml of ethylene diamine tetraacetic acid (EDTA) (Asiachemiteb, Tehran, Iran), followed by 1 ml of 5.25% sodium hypochlorite in order to remove the smear layer. Finally, the WL was confirmed by a master cone and radiography and the canals underwent a final rinse with 5 ml of normal saline. The canals were obturated with a standard #30 gutta-percha cone (META BIOMED Co., Chungbuk, South Korea) in the mesial canal and #35 in the distal canal along with AH-26 sealer (Dentsply Maillefer, Ballaigues, Switzerland). A temporary dressing of zonalin was placed. The final post-treat radiograph showed over extended of sealer in mesial canals.



**Figure 3.** Post-treatment

One week later, the coronal restoration was placed by the patient's dentist without post placement (Figure 3). The first follow-up visit was scheduled for 6 months after root canal treatment. During the follow-up session, no swelling or sensitivity was observed, and radiographic examination revealed that the overfilled sealer and lesion had almost resolved. At the 18 months follow-up, the patient reported that the prosthetic crown had been placed 1-year after the root canal treatment. Clinical examination revealed proper interproximal and occlusal contacts and the clinical and radiographic examination results were normal. No signs and symptoms were observed at 6 months, 2, 4 and 5 and 6 year follow-ups and the periapical lesion had completely repaired (Figures 4-7). The tooth was completely functional with its prosthetic crown.

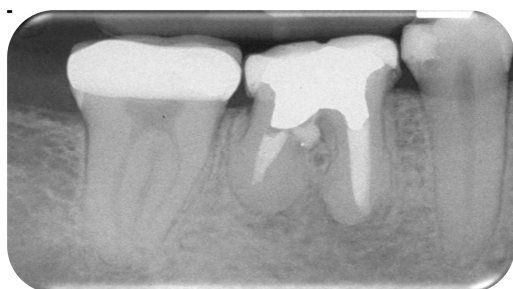


Figure 4. Post-treatment after 6 months

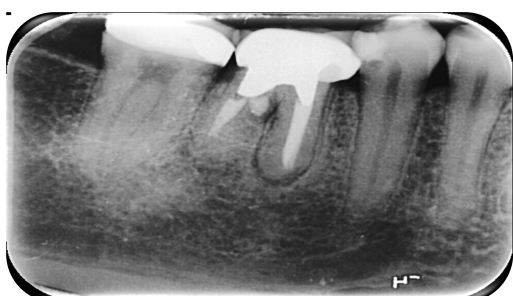


Figure 5. Post-treatment after 2 years

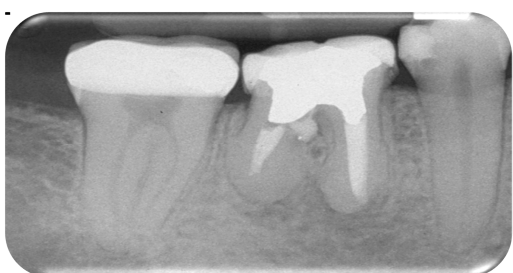


Figure 6. Post-treatment after 4 years

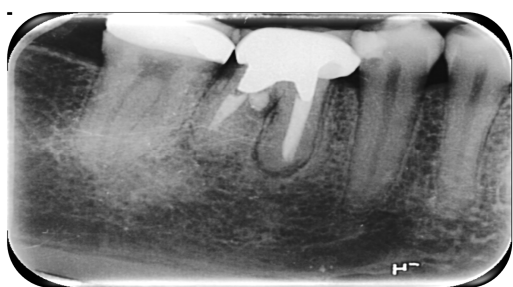


Figure 7. Post-treatment after 6 years

### Discussion

Furcal perforation might occur during root canal therapy, with detrimental effects on treatment results (1;2). Perforations might occur during canal preparation or post space preparation due to inattention to the root long axis. One of the most important

considerations in the repair of perforations is the time interval between the occurrence of perforation and the repair procedure; the success rate increases with a decrease in this time interval.<sup>9,10</sup>

A study by Benenati et al.<sup>11</sup> showed that even delayed perforation repair probably results in recovery on the condition that there is no contamination. In the case presented here, recovery was achieved by creating optimal conditions despite a long time interval between the occurrence of perforation and the repair procedure. One of the considerations during perforation repair is the contamination of dentin around the perforation area, and the area should be disinfected. In cases in which the perforated area is small, sodium hypochlorite is a suitable disinfecting agent. Researchers have recommended the use of 2.5% sodium hypochlorite to this end. Care should be exercised not to extrude sodium hypochlorite in the periodontium due to its pathologic potential. In the present case, too, this material was used for disinfecting the area and controlling the hemorrhage. In most perforation cases, there is hemorrhage during retreatment due to the formation of a granulomatous tissue in the area. Creation of a dry environment improves direct visibility of the area and proper placement of the repair material.<sup>12</sup> In such cases, 2.5% sodium hypochlorite is used to control hemorrhage.<sup>2,13</sup>

Research has shown less microleakage around MTA compared to amalgam and glass-ionomer. Therefore, MTA is the material of choice in the repair of perforations in the furcation area and the root.<sup>3</sup> Contamination of furcation area with blood can influence the quality of the final restoration and retention and sealing ability of MTA. The success rate increases if the lesion around the perforation area is small in size.<sup>12,14</sup> In the present case, the lesion of furcation perforation was small in size, but the time interval between the occurrence of perforation and the repair procedure was



long, success was achieved due to the control of the aseptic conditions, control of hemorrhage and proper placement of the repair material, which was confirmed in the 6 year follow-ups.

A proper technique for remove the smear layer which is clinically applicable is the use of 1 ml 17.0% EDTA, followed by 1 ml 5.25% sodium hypochlorite, each for 1 min.<sup>15</sup> In the present case, this regimen was used for final irrigation.

Various studies<sup>16-18</sup> have shown that subsequent to root canal treatment the final

coronal restoration should be placed as soon as possible in order to prevent coronal leakage and treatment failure. In the present case, the final restoration was placed 1 week after treatment.

### Conflict of Interests

Authors have no conflict of interest.

### Acknowledgments

Authors wish to thank the patient for her corporation.

## References

1. Roda RS. Root perforation repair: surgical and nonsurgical management. *Pract Proced Aesthet Dent* 2001; 13(6): 467-72.
2. Arens DE, Torabinejad M. Repair of furcal perforations with mineral trioxide aggregate: two case reports. *Oral Surg Oral Med Oral Pathol Oral Radiol Endod* 1996; 82(1): 84-8.
3. Ibarrola JL, Biggs SG, Beeson TJ. Repair of a large furcation perforation: a four-year follow-up. *J Endod* 2008; 34(5): 617-9.
4. Breault LG, Fowler EB, Primack PD. Endodontic perforation repair with resin-ionomer: a case report. *J Contemp Dent Pract* 2000; 1(4): 48-59.
5. Samiee M, Eghbal MJ, Parirokh M, Abbas FM, Asgary S. Repair of furcal perforation using a new endodontic cement. *Clin Oral Investig* 2010; 14(6): 653-8.
6. Nakata TT, Bae KS, Baumgartner JC. Perforation repair comparing mineral trioxide aggregate and amalgam using an anaerobic bacterial leakage model. *J Endod* 1998; 24(3): 184-6.
7. Joffe E. Use of mineral trioxide aggregate (MTA) in root repairs. Clinical cases. *N Y State Dent J* 2002; 68(6): 34-6.
8. Tielemans M, Saloukas I, Heyselaer D, Compere P, Nyssen-Behets C, Nammour S. Management of Root Perforations Using MTA with or without Er:YAG Laser Irradiation: An In Vitro Study. *International Journal of Dentistry* 2012; 2012: 5.
9. Vanni JR, Della-Bona A, Figueiredo JA, Pedro G, Voss D, Kopper PM. Radiographic evaluation of furcal perforations sealed with different materials in dogs' teeth. *J Appl Oral Sci* 2011; 19(4): 421-5.
10. Bains R, Bains VK, Loomba K, Verma K, Nasir A. Management of pulpal floor perforation and grade II Furcation involvement using mineral trioxide aggregate and platelet rich fibrin: A clinical report. *Contemp Clin Dent* 2012; 3(Suppl 2): S223-S227.
11. Benenati FW, Roane JB, Biggs JT, Simon JH. Recall evaluation of iatrogenic root perforations repaired with amalgam and gutta-percha. *J Endod* 1986; 12(4): 161-6.
12. Lantz B, Persson PA. Periodontal tissue reactions after surgical treatment of root perforations in dogs' teeth. A histologic study. *Odontol Revy* 1970; 21(1): 51-62.
13. Gernhardt CR, Eppendorf K, Kozlowski A, Brandt M. Toxicity of concentrated sodium hypochlorite used as an endodontic irrigant. *Int Endod J* 2004; 37(4): 272-80.
14. Seltzer S, Sinai I, August D. Periodontal effects of root perforations before and during endodontic procedures. *J Dent Res* 1970; 49(2): 332-9.
15. Serper A, Calt S. The demineralizing effects of EDTA at different concentrations and pH. *J Endod* 2002; 28(7): 501-2.
16. Oliveira SG, Gomes DJ, Costa MH, Sousa ER, Lund RG. Coronal microleakage of endodontically treated teeth with intracanal post exposed to fresh human saliva. *J Appl Oral Sci* 2013; 21(5): 403-8.
17. Siqueira JF, Rôças IN, Ricucci D, Hülsmann M. Causes and management of post-treatment apical periodontitis. *British Dental Journal* 2014; 216: 305-12.
18. Ricucci D, Siqueira JF, Jr. Recurrent apical periodontitis and late endodontic treatment failure related to coronal leakage: a case report. *J Endod* 2011; 37(8): 1171-5.