

## Unusual presentation of primary mandibular gingival squamous cell carcinoma in young male: A case report

*Nishat Sultan MDS<sup>1</sup>, Jyoti R. Rao MDS<sup>2</sup>*

### Case Report

#### Abstract

**BACKGROUND AND AIM:** Squamous cell carcinoma (SCC) is usually considered a disease of older people. Recently, there is a change in the occurrence of such lesions in young patients and lacking the established risk factors.

**CASE REPORT:** A 21-year-old male reported with an innocuous gingival growth over lower incisors since a month. Within 15 days he noticed another gingival growth in same region lingually. The growths were mildly tender with no suppuration. The associated teeth were non-mobile and vital. The radiographic findings were insignificant. An excisional biopsy was performed under local anesthesia. The stained H and E section showed a hyper-parakeratinized stratified squamous surface epithelium with underlying connective tissue with collagen fibers, fibroblasts, blood vessels and areas of dense chronic inflammatory cell infiltrate. Epithelium exhibited features of dysplasia. There was a breach in the continuity of the basement membrane and the malignant epithelial cells were seen invading the connective tissue in form of thin cord.

**CONCLUSION:** The histopathological study confirmed the diagnosis of well differentiated SCC. Oral SCC is not a disease of the elderly anymore. We also reviewed the literature of SCC in young patients. Thus biopsy is mandatory for any non-resolving gingival growth.

**KEYWORDS:** Gingival Overgrowth, Interdental Papilla, Squamous Cell Carcinoma, Gingival Neoplasm, Mandible

**Citation:** Sultan N, Rao JR. Unusual presentation of primary mandibular gingival squamous cell carcinoma in young male: A case report. *J Oral Health Oral Epidemiol* 2015; 4(2): 107-10.

Localized gingival enlargements may indicate many local and systemic conditions.<sup>1</sup> Of all the tumors arising in the oral cavity, more than 90.0% are squamous cell carcinoma (SCC). The overall incidence of gingival carcinoma is < 10.0%.<sup>2</sup> In general; the etiology of malignancies is multifactorial. In spite of the established evidence associating tobacco and alcohol consumption with oral cancer, many of the younger patients with SCC claim to have never smoked or consumed alcohol excessively.<sup>3</sup>

Because of this changing trend, researchers are curious to investigate this clinical entity, whether it is just a variant of the lesion seen in older patients or it is a

distinct lesion, whether the etiology, clinical course and prognosis are same for the two. The purpose of the present report is to describe one such gingival lesion in an otherwise healthy adult.

#### Case Report

A 21-year-old male reported with a painless labial gingival overgrowth of 1-month duration between his lower front teeth. Within 15 days, he noticed another gingival growth at the same location, lingually. His oral hygiene was very good. All the teeth were asymptomatic at the time of presentation. He did not have any drug history. He smoked cigarette 2 or 3 times over the past 1-year only. Before that he was a non-smoker and the

1- Assistant Professor, Department of Periodontology, School of Dentistry, Jamia Millia Islamia, New Delhi, India

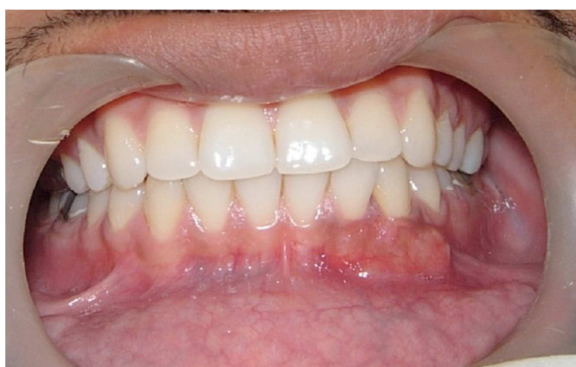2- Professor, Department of Periodontics, Goa Dental College and Hospital, Goa, India

Correspondence to: Nishat Sultan, MDS

Email: nishat\_sultan@rediffmail.com

patient was not smoking at the time of presentation. There was no significant family history of malignancy.

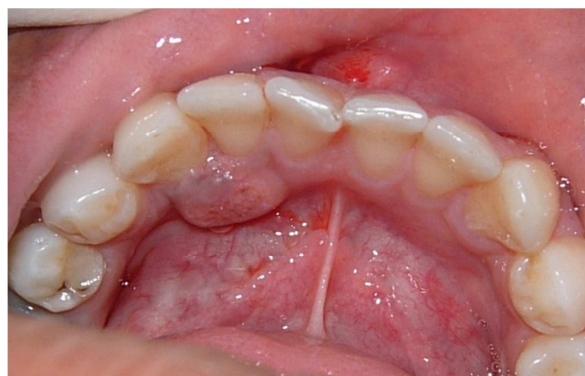On examination, there was a single, isolated 1.5 × 1.0 cm, reddish-pink gingival growth present between 32 and 33. The lesion was firm, fixed and non-mobile (Figure 1). Lingually, there was an isolated gingival growth about 0.7 × 0.7 cm. It was sessile, firm, ovoid, reddish pink, smooth surfaced and non-fluctuant (Figure 2). Both the growths were mildly tender on digital pressure with no discharge and no blanching on pressure. The teeth were non-mobile and vital. There were no signs of involvement of regional lymph nodes. Radiographic examination showed no signs of abnormal bony destruction. All the routine blood tests were within normal limits. An excisional biopsy of both the growths was performed under local anesthesia. Healing was uneventful for the lingual biopsy; however, the labial biopsy site showed minute lobulations during the healing phase.



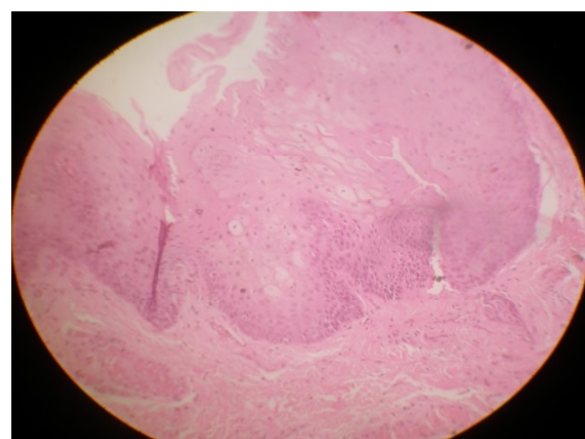
**Figure 1.** Clinical appearance of the labial gingival growth at the initial presentation

The stained H and E section showed a hyper-parakeratinized stratified squamous surface epithelium with underlying connective tissue with collagen fibers, fibroblasts, blood vessels and areas of dense chronic inflammatory cell infiltrate. Epithelium exhibited features of dysplasia like acanthosis, altered nuclear-cytoplasmic ratio, basilar hyperplasia and individual cell keratinization. There was a breach in the

continuity of the basement membrane and the malignant epithelial cells were seen invading the connective tissue in form of thin cord. All the features were suggestive of "well differentiated SCC" (Figure 3).



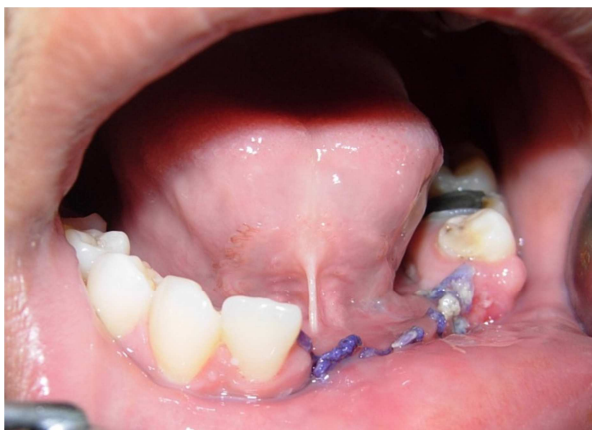**Figure 2.** Clinical appearance of the lingual gingival growth at the initial presentation



**Figure 3.** Histopathological section showing well-differentiated Squamous cell carcinoma (H and E, original magnification × 40)

The patient was referred to Super-Speciality Cancer Hospital where the slides were re-interpreted. More elaborate investigations ruled out the possibility of a metastasis in the body. A wide excision of lower gingivobuccal sulcus with marginal mandibulectomy was performed under general anesthesia along with extraction of teeth 41, 31, 32, 33 and 34 (Figure 4). The histopathological examination re-confirmed the pre-operative diagnosis of a well differentiated SCC (T1N0) of left lower gingivobuccal sulcus. The patient is reviewed

regularly and no evidence of residual neoplastic disease has been detected during 3 years of postsurgical periodic clinical follow-up examination.



**Figure 4.** Clinical image after wide excision of lower gingivobuccal sulcus with marginal mandibulectomy

### Discussion

There is an enormous data related to overall SCC of the mouth, but relatively little is known about the primary gingival SCC. The pioneers Krolls and Hoffman in their extensive review showed that people < 40 years old accounted for only 2.7% of patients presenting with oral cavity and oropharyngeal cancers.<sup>4</sup> Of more than 1000 patients, only 5 patients were < 30 years, among which just a single patient (< 18 years) had a well differentiated SCC of the alveolus. Martin-Granizo et al. studied 505 patients (< 40 years) of oral SCC of oral cavity retrospectively, and found a relatively higher proportion (8.2%) of SCC.<sup>5</sup>

Kuriakose et al. in their retrospective review, reported 4 cases of gingival SCC out of 37 subjects in the age group of 21-34 years, 27 subjects had none of the traditional etiologic factors of tobacco and alcohol abuse.<sup>3</sup> Thompson et al. performed a retrospective review over a 30 years period and documented 20 cases of oral SCC in patients < 20 years.<sup>6</sup>

Adolescent oral SCC of gingiva is exceptionally rare. Few case reports have been

documented in relatively young adults with localized gingival SCC in absence of the traditional risk factors associated with SCC.<sup>7-10</sup> To our knowledge, about 8 cases of gingival SCC have been included in the literature in patients ranging from 4-18 years of age and a predilection for maxillary gingiva was seen.<sup>9</sup>

Our case is an addition to the literature of SCC of gingiva in mandibular arch in young adult. With respect to tobacco and alcohol abuse, it is estimated that smoking and alcohol account for about 75.0% of all cases of oral cancers, but the significance of these factors in young adults is still controversial. Franceschi et al. in their case-control study reported that smoking is a strongly associated with oral cancers in older patients but its role as etiologic agent in young adults is not very significant.<sup>11</sup> This is shared by other descriptive studies too.<sup>3,12</sup> Sasaki et al. evaluated clinicopathological features of oral SCC in young adults (< 40 years). Only 6.6% were < 40 years. Tongue (51.3%) comprised the most common site and gingiva were the least frequent site of SCC.<sup>13</sup>

Udeabor et al. retrospectively studied 977 patients diagnosed histologically of oral and oropharyngeal SCC over 20 years. Various clinical, histological and demographic factors were compared with that of patients younger and older than 40 years. The floor of the mouth comprised the most common site of occurrence (39.5% cases). Younger patients had a better prognosis in terms of long-term overall survival from oral and oropharyngeal SCC.<sup>14</sup> Few case reports of gingival SCC have also been reported in pediatric and adolescents (age 7-14 years).<sup>15-17</sup>

The case presented here is SCC of the anterior mandibular gingiva. Based on the clinical picture and the age of the patient, various benign lesions in its differential diagnosis such as fibrous epulis, peripheral giant cell granuloma, fibroma, or peripheral ossifying (cementifying) fibroma were considered. Histopathological examination is fundamental to establish the malignant nature

of this apparently innocuous looking lesion. Carcinomas of the gingiva in particular tend to present with benign features, and this leads to delays in diagnoses or even misdiagnoses.

Our case report further illustrates the need for vigilance in evaluating and managing an apparent inflammatory oral lesion in young patients. Oral SCC in young patients lack the best known risk factors as seen in SCC in older adults. Further research is needed to investigate the possible confounding or potentiating factors, including genetic, hereditary, dietary, and possible demographic factors in SCC in younger patients. The significance of the present case is as follows:

1. A case of well differentiated SCC of gingiva is reported which is a very rare site of

occurrence, in a young adult, in the absence of the characteristic clinical features associated with SCC, 2. It stresses upon the importance of histopathologic examination as clinical stage at diagnosis is the main predictor of survival of patients with gingival carcinomas, 3. Complete excision of the lesion and an extended follow-up is mandatory.

### Conflict of Interests

Authors have no conflict of interest.

### Acknowledgments

The authors extend their gratitude to Dr. Abhinav Misra and Dr. Gauri Misra for providing the pictomicrograph of the H and E stained section of the gingival biopsy specimen.

### References

1. Glickman I. Glickman's clinical periodontology. 10<sup>th</sup> ed. Philadelphia, PA: Saunders; 2012. p. 125-48.
2. Barasch A, Gofa A, Krutchkoff DJ, Eisenberg E. Squamous cell carcinoma of the gingiva. A case series analysis. *Oral Surg Oral Med Oral Pathol Oral Radiol Endod* 1995; 80(2): 183-7.
3. Kuriakose M, Sankaranarayanan M, Nair MK, Cherian T, Sugar AW, Scully C, et al. Comparison of oral squamous cell carcinoma in younger and older patients in India. *Eur J Cancer B Oral Oncol* 1992; 28B(2): 113-20.
4. Krolls SO, Hoffman S. Squamous cell carcinoma of the oral soft tissues: a statistical analysis of 14,253 cases by age, sex, and race of patients. *J Am Dent Assoc* 1976; 92(3): 571-4.
5. Martin-Granizo R, Rodriguez-Campo F, Naval L, Diaz Gonzalez FJ. Squamous cell carcinoma of the oral cavity in patients younger than 40 years. *Otolaryngol Head Neck Surg* 1997; 117(3 Pt 1): 268-75.
6. Thompson L, Castle J, Heffner D. Oral squamous cell carcinoma in pediatric patients: a clinicopathologic study of 20 cases. *Oral Surg Oral Med Oral Pathol* 1999; 88: 204.
7. Meleti M, Corcione L, Sesenna E, Vescovi P. Unusual presentation of primary squamous cell carcinoma involving the interdental papilla in a young woman. *Br J Oral Maxillofac Surg* 2007; 45(5): 420-2.
8. Tolman A, Jerrold L, Alarbi M. Squamous cell carcinoma of attached gingiva. *Am J Orthod Dentofacial Orthop* 2007; 132(3): 378-81.
9. Woo VL, Kelsch RD, Su L, Kim T, Zegarelli DJ. Gingival squamous cell carcinoma in adolescence. *Oral Surg Oral Med Oral Pathol Oral Radiol Endod* 2009; 107(1): 92-9.
10. Alsharif MJ, Jiang WA, He S, Zhao Y, Shan Z, Chen X. Gingival squamous cell carcinoma in young patients: report of a case and review of the literature. *Oral Surg Oral Med Oral Pathol Oral Radiol Endod* 2009; 107(5): 696-700.
11. Franceschi S, Barra S, La VC, Bidoli E, Negri E, Talamini R. Risk factors for cancer of the tongue and the mouth. A case-control study from northern Italy. *Cancer* 1992; 70(9): 2227-33.
12. Byers RM. Squamous cell carcinoma of the oral tongue in patients less than thirty years of age. *Am J Surg* 1975; 130(4): 475-8.
13. Sasaki T, Moles DR, Imai Y, Speight PM. Clinico-pathological features of squamous cell carcinoma of the oral cavity in patients <40 years of age. *J Oral Pathol Med* 2005; 34(3): 129-33.
14. Udeabor SE, Rana M, Wegener G, Gellrich NC, Eckardt AM. Squamous cell carcinoma of the oral cavity and the oropharynx in patients less than 40 years of age: a 20-year analysis. *Head Neck Oncol* 2012; 4: 28.
15. Earle AS, Park CH, Vlastou C. Oral squamous cell carcinoma in children. *Ann Plast Surg* 1988; 20(2): 148-52.
16. Sacks HG, Holly R, Blum B, Joy ED. Case 58: maxillary alveolar mass in a 13-year-old boy. *J Oral Maxillofac Surg* 1985; 43(12): 958-63.
17. Bill TJ, Reddy VR, Ries KL, Gampper TJ, Hoard MA. Adolescent gingival squamous cell carcinoma: Report of a case and review of the literature. *Oral Surg Oral Med Oral Pathol Oral Radiol Endod* 2001; 91(6): 682-5.