

Case Report**Rare cavernous haemangioma of the oral cavity with numerous phleboliths**Maryam Alsadat Hashemipour DDS, MSc¹**Abstract**

Hemangiomas are tumors of blood vessels identified by rapid endothelial cell proliferation in early infancy followed by involution over time. All other abnormalities are malformations resulting from anomalous development of vascular plexuses. This lesion in the oral cavity is not common. Despite its benign origin and behaviour, it is always of clinical importance to the dental profession and requires appropriate management. This paper reports a rare case of cavernous hemangioma of base of tongue, buccal mucosa and floor of mouth with extensive phleboliths in a 64-year-old male.

KEY WORDS: Oral, hemangiomas, vascular malformation, phlebolith, tongue, buccal mucosa.

J Oral Health Oral Epidemiol 2012; 1(1): 46-51

The term hemangioma has been commonly misused to describe a large number of vasoformative tumors.¹ These lesions represent the most common growths in infancy and childhood, and may vary from small innocent birthmarks to large disfiguring tumors.^{2,3} Hemangiomas usually appear 2-4 weeks after birth; grow rapidly till the age of 6-8 months and then slowly develop. By age 5-8 years, they start to involute and spontaneously regress in 70% of the cases.⁴ There are many ways to classify hemangiomas. According to Enzinger and Weiss, hemangiomas are broadly classified into capillary, cavernous, and miscellaneous forms like verrucous, venous, arteriovenous haemangiomas, and so forth.⁵

The majority of haemangiomas involve the head and neck. However, they are rare in the oral cavity but may occur on tongue, lips, buccal mucosa, gingiva, palatal mucosa, salivary glands, alveolar ridge, and jaw bones.^{1,5,6} Females appear to have a slightly higher incidence than males.⁷

Changes in blood flow dynamic within hemangiomas result in thrombus and phleboliths. Phleboliths are calcified nodules that can be regarded as a characteristic property of

venous or cavernous hemangiomas.⁸ Phlebolith formation reported as a characteristic feature of hemangiomas was first described in the splenic vein. Although hemangioma is a relatively common lesion in the head and neck region, it is rarely associated with phlebolith in the region.⁹ Phleboliths are calcified thrombi occur in venules, veins, or sinusoidal vessels of hemangiomas involving the soft tissues adjacent to the jaws. They are always coincidental with vascular stasis. They may occur singly or as multiple calcifications, are usually small radiopacities, may be round or oval, and always coincidental with involving the soft tissues adjacent to the jaws. When they are projected over the mandibular bone or the periapices of mandibular teeth, they may easily be confused with sialoliths. They should also be differentiated from salivary gland calculi, tonsilloliths, calcified lymph nodes, soft tissue tumors, calcification of arteries, antrolith, multiple miliarystomas of skin, myositis ossificans, calcified acne and cysticercosis.¹⁰

After an extensive search of the English language literature, only 23 cases of head & neck hemangiomas with phleboliths were properly documented. Seven cases have been reported

¹ Assistant Professor, Kerman Oral and Dental Diseases Research Center, Department of Oral Medicine, School of Dentistry, Kerman University of Medical Sciences, Kerman, Iran.

Correspondence to: Maryam Alsadat Hashemipour DDS, MSc.
Email: m_hashemipour@kmu.ac.ir

in buccal mucosa or cheek,¹¹⁻¹⁶ ten cases were in the parotid, submandibular glands and submental,¹⁷⁻²⁴ one case was in the floor of the mouth,⁸ one case was in the hypopharynx,²⁵ three cases were on masseter²⁶⁻²⁸ and one case was in the parapharyngeal space.²⁹ Here, we show a relatively rare and unusual case of venous hemangiomas of base of tongue, buccal mucosa and floor of mouth with extensive phleboliths.

Case Report

A 64 year old man was referred to the department of oral medicine, Kerman Dental School, by his physician for evaluation of a swelling on the left side of the tongue, buccal mucosa, ridge of mandible and floor of mouth. According to the patient, this lesion existed from childhood and it had slowly increased in size. For the past 3 months, the swelling in tongue gradually developed causing dysphagia, repeated bleeding and speech problems. There were no associated features of pain or fever. The patient did not have systemic disease and on physical examination, he appeared to be healthy and of normal size and weight. The rest of the general physical examinations were within normal limits.

Oral examination demonstrated a 4.5 × 4.0 cm cobblestone soft tissue mass on the left side of the tongue with diffuse margins and the lesion was occupying almost the whole anterior 2/3 of the tongue (Figure 1). Moreover, the buccal mucosa, mandibular ridge, hard palate and

floor of the oral cavity in the left side were involved (Figure 2). The surface appeared to be smooth and the mucosal covering was dark purple in color with no break or ulceration that blanched slightly under pressure. The lesion was non-tender and firm in consistency. The remainder of the oral examination was essentially normal. No positive cervical lymphadenopathy could be detected. The skin of face overlying the lesion had normal color. Aspiration was done, which yielded only blood.

A panoramic X-ray of the area demonstrated 4.5 cm by 5.5 cm radiolucency in the left side of the mandible, with an ill-defined and irregular border. Furthermore, 17 radiopaque lesions measuring between 2 to 10 mm were seen in the area of soft tissue (Figure 3).

A diagnosis of hemangiomas with differential diagnosis of an angiosarcoma, hemangiosarcoma, pyogenic granuloma and Kaposi's sarcoma was made. Under general anesthesia, simple enucleating of friable tissue from left cheek was performed. Blood transfusion was not needed and no complications occurred.

Histological examination of the excised soft tissue showed typical feature of hemangiomas (Figure 4). Because we found phleboliths and thrombus in the hemangioma, we diagnosed this case as cavernous hemangioma with phleboliths in the oral cavity in accordance with preoperative diagnosis. Unfortunately, since the patient was referred by his physician, despite repeated calls, he did not refer for further treatment.

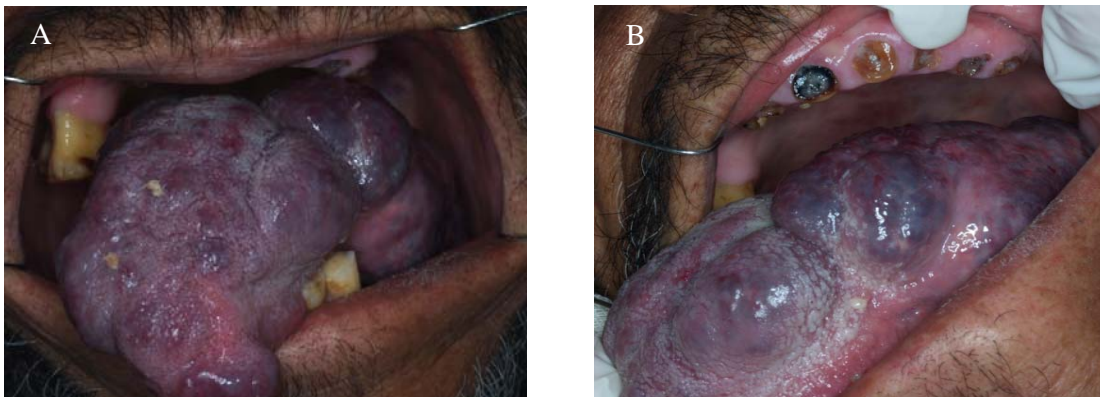


Figure 1. A cobblestone soft tissue mass on the left side of the tongue (A, B)

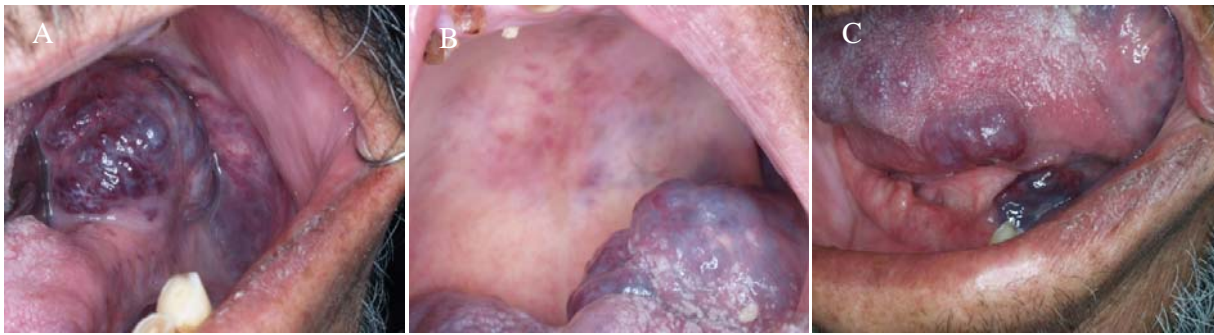


Figure 2. Soft tissue mass on the buccal mucosa and mandibular ridge (A), hard palate (B) and floor of the oral cavity(C)

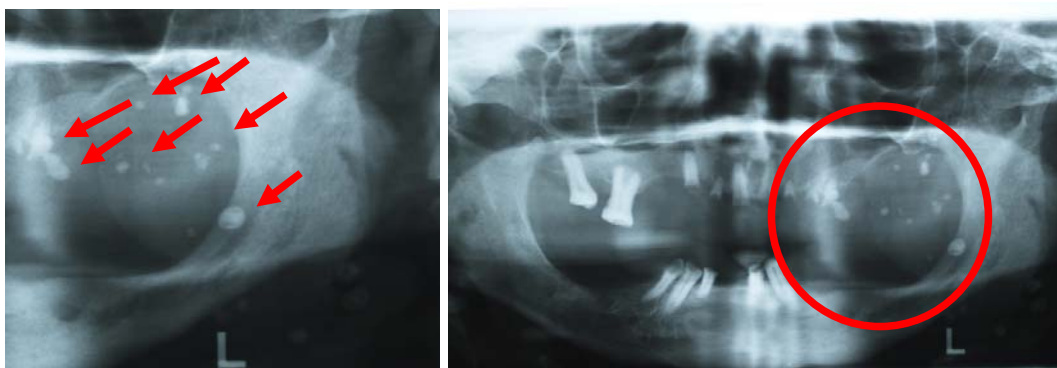


Figure 3. The radiopaque lesions measuring between 2 to 10 mm was seen in the area of soft tissue.

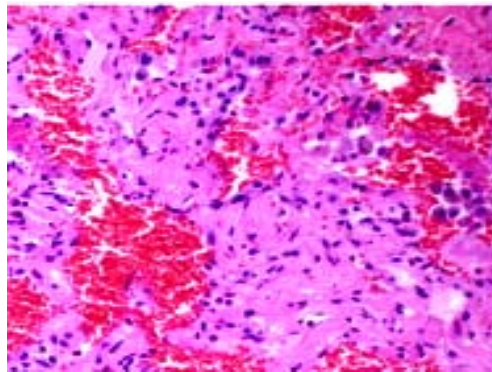


Figure 4. Microscopically, specimen demonstrated hemangiomatous in the buccal mucosa (H&E, x 4)

Discussion

Bormann first used the term hemangioendothelioma in 1899.³⁰In 1908, Mallory used the term malignant vascular tumor for this lesion.³¹ Stout described the histological features of hemangiomas in 1944.³² Hemangiomas are the most common soft tissue tumor of childhood^{11,33,34} and head and neck region is the most common site for hemangiomas development (about 60% of cases).³⁴To our

knowledge, we presented the first case of hemangiomas with multiple phleboliths in the lingual, buccal mucosa, mandibular ridge, hard palate and floor of oral cavity.

Lingual hemangiomas pose distressing problems to the patients, producing cosmetic deformity, recurrent hemorrhage, and functional problems with speaking, deglutition, and mastication.³⁵Among the different sites of head and neck hemangiomas, the tongue re-

quires special consideration because of its susceptibility to minor trauma and consequent bleeding and ulceration, swallowing difficulties and breathing problem; although, the major concern is cosmetic in most cases.³⁶In our case, no similar lesion was found in other body systems and the mouth was the only site for the hemangiomas; whereas 20% of hemangiomas are present at more than one site.³⁷

The clinical appearance of this tumor is similar to that of many other vascular tumors. The hemangioma appears as soft mass, smooth or lobulated, and sessile or pedunculated and may vary in size from a few millimeters to several centimeters. They are usually deep red and may blanch on the application of pressure and if large in size, might interfere with mastication.⁶ Our case was clinically similar to those above described. The differential diagnosis for our case were angiosarcoma, hemangiosarcoma, pyogenic granuloma and Kaposi's sarcoma, that considering course of lesion (started in childhood), lesion color (reddish purple), no bleeding, multiple lesion in the mouth, positive diascopy and radiographic findings (phleboliths) diagnosis of hemangiomas was made for it.

Hemangioma is characterized by increased number of normal or abnormal vessels filled with blood that by vascular tissue is connected to an artery or vein. In some patients, it is likely that the connecting vessel involved with stasis or torque and in these people when this problem is resolved for reasons such as trauma, hemangiomas get larger in size.

Hemangiomas may be associated with cutaneous lesions, a strong diagnostic point. Malignant transformation is not reported.²³They may rarely enlarge rapidly, causing local deformity and loss of function. Though it is usually painless, there are several reports of pain associated with vascular tumors.^{38,39}Because of the danger of hemorrhage, aspiration and biopsy is not recommended for diagnosis of hemangiomas;

however, as way to diagnose this lesion it was used by many researchers.^{40,41}

Hemangiomas, because of their tendency to involute and regress spontaneously, are generally managed conservatively, usually by close follow up and observation. Intervention is indicated only if the lesion starts to bleed, ulcerates, or interferes with function. Various treatment methods have been reported, and there are still controversies over the selection of different treatment modalities. Several treatment modalities are suggested for these lesions including surgical, cryosurgery, intralesional administration of corticosteroids or sclerosant (sodium tetracycl), radiotherapy, and embolization with steel coil, gel foam, silicone beads or cyanoacrylate. In contrast to vascular malformations, most hemangiomas regress in response to medical treatment or with conservative managements.^{40,41}

Cankaya et al. reported a hemangioma with phleboliths in the sublingual gland.¹⁸The research methods such as clinical examination, ultrasonography, computed tomography and biopsy were used to detect Hemangiomas. Baba and Kato reported a case of hemangioma with phleboliths in the floor of the mouth and Doppler ultrasonography, CT, magnetic resonance imaging (MRI) and biopsy was used to diagnose the lesion.⁸Other researches used similar methods to diagnose hemangiomas with phleboliths.^{8,12,13,17-19,23,24,28,42}

Conclusion

The hemangioma with phleboliths is a rare tumor of the oral cavity. We present the first reported case of cavernous hemangiomas occurring in the oral cavity with phleboliths. Hemangiomas with phleboliths should be considered in the differential diagnosis of swellings of the oral cavity.

Conflict of Interest

Authors have no Conflict of Interest.

References

1. Lanza A, Gombos F. A case of multiple oral vascular tumours: the diagnostic challenge on haemangioma still remains open. *The Journal of Stomatological Investigation* 2008; 2(1): 67-71.

2. Mulliken JB, Glowacki J. Hemangiomas and vascular malformations in infants and children: a classification based on endothelial characteristics. *Plast Reconstr Surg* 1982; 69(3): 412-22.
3. Kaban LB, Mulliken JB. Vascular anomalies of the maxillofacial region. *J Oral Maxillo fac Surg* 1986; 44(3): 203-13.
4. Apfelberg DP. Treatment of hemangiomas. In: Georgiade GS, Georgiade NG, editors. *Textbook of Plastic, Maxillofacial and Reconstructive Surgery*. 2nd ed. Philadelphia, PA: Williams & Wilkins; 1992.
5. Enzinger FM, Weiss SW. *Soft Tissue Tumors*. 5th ed. St. Louis: CV Mosby.; 2001.
6. Gill JS, Gill S, Bhardwaj A, Grover HS. Oral Haemangioma. *Case Report Med* 2012; 2012: 347939.
7. Shklar G, Meyer I. Vascular Tumors of The Mouth and Jaws. *Oral Surg Oral Med Oral Pathol* 1965; 19: 335-58.
8. Baba Y, Kato Y. Hemangioma with Phleboliths in the Floor of the Mouth Presenting as a Submental Swelling: A Case Report. *Journal of Medical Cases* 2011; 2(1): 28-30.
9. Dempsey EF, Murley RS. Vascular malformations simulating salivary disease. *Br J Plast Surg* 1970; 23(1): 77-84.
10. Zachariades N, Rallis G, Papademetriou J, Konsolaki E, Markaki S, Mezitis M. Phleboliths. A report of three unusual cases. *Br J Oral Maxillo fac Surg* 1991; 29(2): 117-9.
11. Kutluhan A, Bozdemir K, Ugras S. The treatment of tongue haemangioma by plasma knife surgery. *Singapore Med J* 2008; 49(11): e312-e314.
12. Kanaya H, Saito Y, Gama N, Konno W, Hirabayashi H, Haruna S. Intramuscular hemangioma of masseter muscle with prominent formation of phleboliths: a case report. *Auris Nasus Larynx* 2008; 35(4): 587-91.
13. Sano K, Ogawa A, Inokuchi T, Takahashi H, Hisatsune K. Buccal hemangioma with phleboliths. Report of two cases. *Oral Surg Oral Med Oral Pathol* 1988; 65(2): 151-6.
14. Ikegami N, Nishijima K. Hemangioma of the buccal pad with phlebolithiasis: report of a case. *Acta Med Okayama* 1984; 38(1): 79-87.
15. Hemmati A. Phleboliths in a Hemangioma of the left Cheek. *Fortschr Geb Rontgenstr Nuklearmed* 1965; 102: 210-1. [In German].
16. Krause D. Multiple Phleboliths in a Cavernous Hemangioma of the Cheek. *Z Laryngol Rhinol Otol* 1964; 43: 125-7. [In German].
17. Altug HA, Buyuksoy V, Okcu KM, Dogan N. Hemangiomas of the head and neck with phleboliths: clinical features, diagnostic imaging, and treatment of 3 cases. *Oral Surg Oral Med Oral Pathol Oral Radiol Endod* 2007; 103(3): e60-e64.
18. Cankaya H, Unal O, Ugras S, Yuca K, Kiris M. Hemangioma with phleboliths in the sublingual gland: as a cause of submental opacity. *Tohoku J Exp Med* 2003; 199(3): 187-91.
19. Chuang CC, Lin HC, Huang CW. Submandibular cavernous hemangiomas with multiple phleboliths masquerading as sialolithiasis. *J Chin Med Assoc* 2005; 68(9): 441-3.
20. Brands T. Hemangioma of the parotid gland with multiple phleboliths. *Zentralbl Chir* 1969; 94(32): 1064-7. [In German].
21. NEUSS O. Multiple phleboliths in an angioma of the parotid gland. *Z Laryngol Rhinol Otol* 1958; 37(4): 240-2. [In German].
22. Bartak J. Phleboliths in a hemangioma in the parotidomasseteric region. *Cesk Stomatol* 1967; 67(2): 126-8. [In Czech].
23. McMenamin M, Quinn A, Barry H, Sleeman D, Wilson G, Toner M. Cavernous hemangioma in the submandibular gland masquerading as sialadenitis: case report. *Oral Surg Oral Med Oral Pathol Oral Radiol Endod* 1997; 84(2): 146-8.
24. Sleiter R, Altermatt HJ, Buser D, Bornstein M. Cavernous hemangioma in the masseter muscle with multiple phlebolith formation: a case report. *Schweiz Monatsschr Zahnmed* 2002; 112(6): 617-23. [In French, German].
25. Li X. Rare cavernous haemangioma of the hypopharynx with numerous phleboliths. *J LaryngolOtol* 1990; 104(3): 262-3.
26. Bernadskii I, Khimich AI, Kucher GD. Racemose facial hemangioma with multiple phleboliths. *Stomatologiia (Mosk)* 1983; 62(1): 79. [In Russian].
27. Schwartz A, Salz N. Cavernous hemangioma associated with phleboliths in the masseter muscle. *Actaradiol* 1955; 43(3): 233-4.
28. Mohan RPS, Dhillon M, Gill N. Intraoral venous malformation with phleboliths. *Saudi Dent J* 2011; 23(3): 161-3.
29. Cho JH, Joo YH, Kim MS, Sun DI. Venous hemangioma of parapharyngeal space with calcification. *Clin Exp Otorhinolaryngol* 2011; 4(4): 207-9.
30. Borrmann R. Metastaserbildung bis histologisch gutartigin Geschuulsten (fall metastasierendem Anjou). *Beitr z Path Anat* 1907; 40: 372.
31. Mallory FB. The Results of The Application of Special Histological Methods to the Study of Tumors. *J Exp Med* 1908; 10(5): 575-93.
32. Stout AP. Hemangio-Endothelioma: A tumor of Blood Vessels Featuring Vascular Endothelial Cells. *Ann Surg* 1943; 118(3): 445-64.

33. Eivazi B, Ardelean M, Baumler W, Berlien HP, Cremer H, Elluru R, et al. Update on hemangiomas and vascular malformations of the head and neck. *Eur Arch Otorhinolaryngol* 2009; 266(2): 187-97.
34. Werner JA, Dunne AA, Folz BJ, Rochels R, Bien S, Ramaswamy A, et al. Current concepts in the classification, diagnosis and treatment of hemangiomas and vascular malformations of the head and neck. *Eur Arch Otorhinolaryngol* 2001; 258(3): 141-9.
35. Brown DA, Smith JD. Late complication of congenital hemangioma of the tongue. *Head Neck Surg* 1987; 9(5): 299-304.
36. Chang CJ, Fisher DM, Chen YR. Intralesional photocoagulation of vascular anomalies of the tongue. *Br J Plast Surg* 1999; 52(3): 178-81.
37. Dilsiz A, Aydin T, Gursan N. Capillary hemangioma as a rare benign tumor of the oral cavity: a case report. *Cases J* 2009; 2: 8622.
38. Calhoun JJ. Malignant hemangioendothelioma (angiosarcoma). *Oral Surg Oral Med Oral Pathol* 1969; 27(2): 156-60.
39. Gandhi EK, Kinare SG, Parulkar GB, Sen PK. Hemangiosarcoma (malignant hemangioendothelioma) of the mandible in a child. *Oral Surg* 1966; 22(359): 362.
40. El Abdin H, Haidar Z. Hemangioma of the tongue: a conservative treatment with circumferential ligation. *Saudi Dental Journal* 2012; 10(1): 18-22.
41. Zheng JW, Zhou Q, Yang XJ, Wang YA, Fan XD, Zhou GY, et al. Treatment guideline for hemangiomas and vascular malformations of the head and neck. *Head Neck* 2010; 32(8): 1088-98.
42. Ingalls GK, Bonnington GJ, Sisk AL. Intramuscular hemangioma of the mentalis muscle. *Oral Surg Oral Med Oral Pathol* 1985; 60(5): 476-81.