

## Absorbed dose of sensitive organs in maxillofacial region by different radiographic techniques: Panoramic, Waters, Caldwell and cone-beam computed tomography

Seyed Hosein Hoseini-Zarch DDS, MSc<sup>1</sup>, Mohammad Taghi Bahreyni PhD<sup>2</sup>, Fatemeh Akbari MSc<sup>3</sup>, Nasim Khaki PhD, DDS, MD<sup>4</sup>, Mona Poorazad DDS<sup>5</sup>

### Original Article

#### Abstract

**BACKGROUND AND AIM:** Due to increasing use of X-rays in diagnosis and treatment of diseases, this study aimed to measure and compares the absorbed dose in a number of sensitive organs of head and neck in different radiographic techniques.

**METHODS:** Thermoluminescence dosimeter (TLD) and a male equivalent RANDO phantom were used to measure the absorbed dose in organs. The dosimeters were set in certain sites of phantom related to eye, parotid, thyroid gland, occipital area and temporomandibular joint (TMJ). Panoramic and Caldwell techniques with two different exposure conditions as well as Waters technique with three different exposure conditions were performed. Cone-beam computed tomography (CBCT) was applied in low and normal resolutions with different field of view (FOV), and the mean absorbed dose was calculated and compared by the dosimeters related to each of the organs.

**RESULTS:** The panoramic imaging technique revealed the lowest dose for the eyes, but interestingly higher doses for the parotid gland and the occipital area. In total, Waters and Caldwell imaging techniques indicated that the occipital area and the parotid gland absorbed a higher dose than other organs. In the majority of CBCT scans the parotid region received the highest dose. However, during sinus CBCT (both in low-dose and high-dose modes), the TMJ and eye areas absorbed the highest dose. Investigation of the use of thyroid shield on the absorbed dose in this organ in CBCT showed an average 22% reduction in dose.

**CONCLUSION:** In total, panoramic, Waters and Caldwell imaging techniques indicated that the occipital area and the parotid gland absorbed a higher dose than other organs. In the majority of CBCT scans, the parotid region received the highest dose.

**KEYWORDS:** Radiation Dosimeters; Absorption; Radiation; Cone-Beam Computed Tomography; Panoramic Radiography

**Citation:** Hoseini-Zarch SH, Bahreyni MT, Akbari F, Khaki N, Poorazad M. Absorbed dose of sensitive organs in maxillofacial region by different radiographic techniques: Panoramic, Waters, Caldwell and cone-beam computed tomography. *J Oral Health Oral Epidemiol* 2017; 6(3): 121-9.

After discovery of X-ray in 1895, application of this beam expanded quickly in all fields, without much precautionary protection or worries about its possible harmful effects. However, the damaging effects of this type of radiation soon began to show up and raise concerns.

Consequently, X-ray and radioactive materials are currently used with extra care, although the application of X-ray is ever more expanding in the medical domain due to its capacity for diagnosis and treatment of diseases.<sup>1</sup>

The knowledge of the biological effects of

1- Associate Professor, Dental Materials Research Center AND Department of Oral and Maxillofacial Radiology, School of Dentistry, Mashhad University of Medical Sciences, Mashhad, Iran

2- Professor, Medical Physics Research Center AND Department of Medical Physics, School of Medical Sciences, University of Mashhad, Mashhad, Iran

3- Medical Physics Research Center AND Department of Medical Physics, School of Medical Sciences, University of Mashhad, Mashhad, Iran

4- MSc Student, School of Dentistry, Mashhad University of Medical Sciences, Mashhad, Iran

5- Private Practice, Mashhad, Iran

Correspondence to: Nasim Khaki PhD, DDS, MD

Email: nasim.khaki.84@gmail.com

ionizing radiation and realizing the fact that the corresponding dosage impacts the presentation of these effects led to increased protection for patients and radiographers during application. In this context, dosimetry becomes an essential measure both in radiography and radiotherapy.

By definition, dosimetry is concerned with determining the quantity of radiation exposure or dose. The term "absorbed dose" is used to specify the amount of energy absorbed by a given unit of material within the target region.<sup>2</sup>

Thermoluminescence dosimetry (TLD) is used as an appropriate method for measurement of dose in diagnostic radiology.<sup>3</sup> The greatest advantages of TLD materials are their small size and their flexibility, which allow for their insertion into the target material in order to measure the absorbed dose without significantly changing the radiation field. They are quite robust and do not require any connector or wiring.<sup>4</sup> In vivo insertion of dosimetry material is impossible in many cases, and therefore the measurement of dose is restricted to superficial organs such as testes, thyroid and crystalline lenses. For these cases, the TLD material is attached to the skin at the region of the desired organ. In view of the limitations, anthropomorphic physical phantoms can be employed to accurately measure the dose for internal organs. The amount of beam absorption and scattering of these phantoms is similar to that of natural tissues in human body.<sup>5</sup>

The panoramic imaging technique, used for screening radiography, is rapidly gaining popularity among dentists for routine dental examination. Also, Waters and Caldwell techniques have traditionally been used for screening radiography when evaluating the paranasal sinuses. Recently, however, Cone-Beam Computed Tomography (CBCT) has been introduced as a superior technique, and various studies have indicated a lower dose during application of this technique compared with computed tomography (CT).

Besides, the quality of sinus radiographs obtained from CBCT is much higher than that produced by conventional radiography. This study aimed to evaluate and compare the absorbed dose resulting from these different techniques, while noting the advantages and drawbacks of each technique.

## Methods

In this descriptive study, 100 cubic LiF: Mg, Ti TLDs (Thermoluminescent dosimeters) were used (TLD-100, Harshaw Company, USA).

TLDs were calibrated with diagnostic X-ray beams at 70 kVp using a Radcal-type calibrated ionization chamber, specialized for diagnostic X-ray beams. TLDs require annealing during the calibration procedure, and thus they were initially placed in the furnace at 400 °C for one hour. Then, they were removed from the furnace and left to cool slowly. Once again, they were put in the furnace at 100 °C for 2 hours, followed by a second cooling period. Upon completion of annealing, and once the TLDs were coded during calibration, they were placed in their plastic cassettes to shield them from any contamination.

In order to use TLDs for each new radiation, the possible residual energy from previous exposures had to be eliminated. For this purpose, an electric furnace (1200 model, Exciton Company, Iran) was deployed, which resided in the Medical Physics Research Center of Mashhad University of Medical Sciences, Mashhad, Iran.

RANDO phantoms (Figure 1) are specialized tools available for treatment planning in radiotherapy and can also be used in diagnostic radiology. The phantom is generally composed of 35 slices (0 to 34) and includes head and trunk (Figure 2). Each phantom slice comprises bone, red bone marrow, soft tissue and skin. The diagram of each slice features vertical and horizontal axes which define the anterior and posterior positions.<sup>6</sup>

Phantom slices are tightly held together by aluminum plates secured on the uppermost (0) and lowermost (34) slices.



**Figure 1.** RANDO phantom of the head and neck (Model 706-C; Computerized Imaging Reference Systems Inc., Norfolk, VA)

The phantoms come in two models of average size, a male and a female type, designed with the following specifications:

- The female phantom: 163 cm tall weighing 54 kg.
- The male phantom: 175 cm tall weighing 73.5 kg.

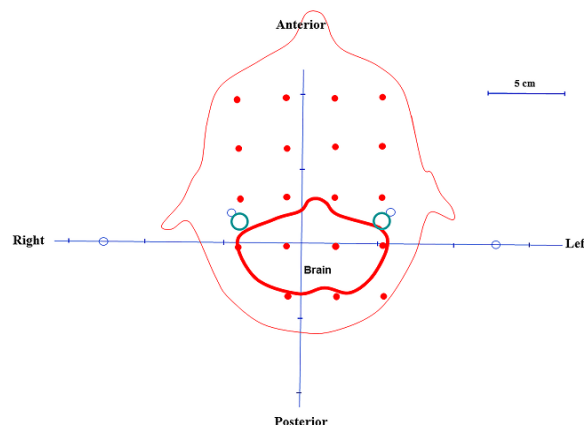


**Figure 2.** Different slices of phantom

Both phantoms contain an anthropomorphic skeleton stuffed with tissue-like materials.<sup>6</sup>

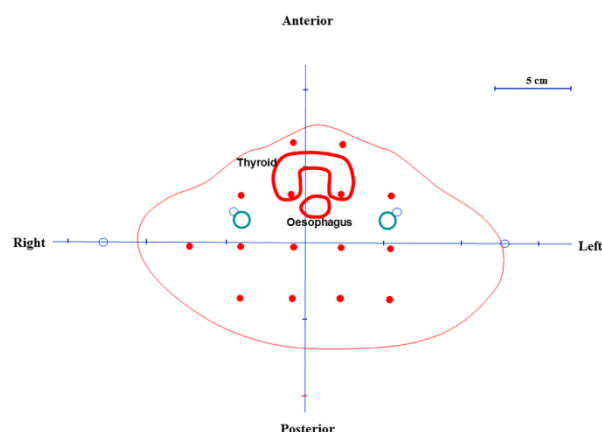
This study utilized a male RANDO phantom to ensure smooth application of TLDs in the region of each intended organ. Only the head and neck segments of the phantom were used, since all target organs of the study were located in this region. After consultation with anatomy specialists of MUMS and review of pertinent literature, the dosimeters corresponding to the occipital area and the temporomandibular joint (TMJ)

were placed in slices No. 8 and No. 4 of the phantom, respectively and those related to the thyroid (Figure 3), eyes and the parotid region were placed in slices No. 9, 3 and 6, respectively (Figure 4-6).

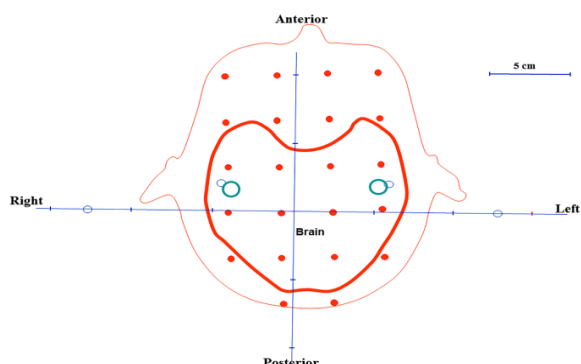


**Figure 3.** Schematic view of the fourth slice for the location of the thermoluminescent dosimeters (TLD)

Four TLD chips were registered within the anterior region of slice No. 9 for the thyroid gland and 2 TLD chips within slice No. 8 for the occipital area. One TLD chip was positioned in each side of the TMJ, the parotid gland and the eyes in the corresponding slices (No. 4, 6 and 3, respectively), and the mean of the doses recorded by each pair of the corresponding TLDs was calculated in order to establish the dose these organs received.

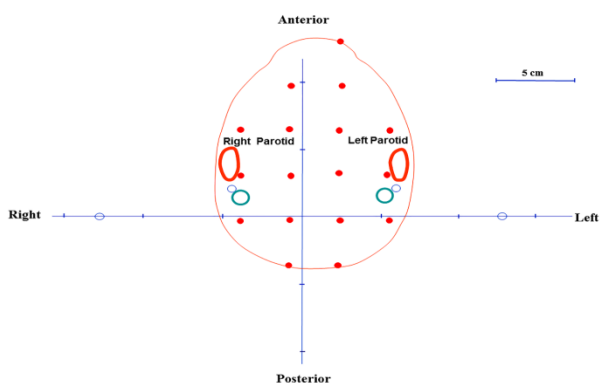


**Figure 4.** Schematic view of the ninth slice for the location of the thermoluminescent dosimeters (TLD)



**Figure 5.** Schematic view of the third slice for the location of the thermoluminescent dosimeters (TLD)

For Waters and Caldwell radiographic examinations, the phantom was fixed in place using the machine's bars and then set at the desired angle. During panoramic radiography and CBCT, the phantom's head was laid straight without any angle on a legged table.



**Figure 6.** Schematic view of the sixth slice for the location of the thermoluminescent dosimeters (TLD)

Panoramic imaging as well as Waters and Caldwell radiography were conducted using the Planmeca machine (ProlineXC 2007 model, Finland). Waters and Caldwell techniques were carried out employing the cephalometric arm of the panoramic device. The images were digitalized using a

computed radiography (CR) machine with pixel size of 86  $\mu\text{m}$  (CR-110, Konica). The device features rectangular collimation and its total filtration is equivalent to 2.5 mm of aluminum. Exposure conditions of the conventional techniques are presented in table 1.

Three-dimensional tomography was conducted using a Planmeca machine (ProMax3D 2009 model, Finland), which offers a resolution of 320  $\mu\text{m}$  on the low-dose mode and 160  $\mu\text{m}$  on the normal mode. The field of view (FOV) of the machine was as follows: large (8 cm  $\times$  14 cm), medium (8 cm  $\times$  8 cm, single jaw: 8 cm  $\times$  5 cm) and small (5 cm  $\times$  4 cm). This device boasts rectangular collimation and its total filtration is equivalent to 2.5 mm of aluminum and 0.5 mm of copper.

The following configurations were used when employing the CBCT device: mA = 8 and kVp = 80. The radiation beams covered four regions: maxilla, mandible, maxilla and mandible together, and the maxillary sinus. Radiography was performed for all four regions in both normal and low-dose modes. As for sinus CBCT, the Stitch technique with FOV = 8 cm  $\times$  14 cm was applied to increase the radiation field (Table 2). CBCT imaging was performed under three varied conditions with normal resolution and with three different FOVs: using a thyroid shield (CBCT images 7, 8 and 9) to measure the thyroid dose and compare it with similar positions; and also without the thyroid shield (CBCT images 1, 3 and 5). At the end of each radiography session performed according to a specific exposure setting, the TLDs were removed and replacement TLDs were prepared and placed again in the set regions of the organ so as to be radiated according to different exposure conditions.

**Table 1.** Exposure conditions of conventional techniques

Radiography technique	Setting		
	First time	Second time	Third time
Panoramic	mA = 5, kVp = 66, t = 18	mA = 10, kVp = 66, t = 18	-
Waters	mA = 6, kVp = 78, t = 1.2	mA = 12, kVp = 78, t = 1.2	mA = 12, kVp = 80, t = 2.3
Caldwell	mA = 12, kVp = 76, t = 1	mA = 12, kVp = 80, t = 2.6	-

**Table 2.** Exposure conditions in cone-beam computed tomography (CBCT) radiography

Organs	mA, kVp	CBCT	Resolution	Time (s)	Thyroid shield	FOV (cm)
Maxilla and mandible (full)	8, 80	CBCT 1	N	12.0	-	8 × 8
		CBCT 2	LD	2.8	-	
Maxilla	8, 80	CBCT 3	N	12.0	-	8 × 5
		CBCT 4	LD	2.8	-	
Mandible	8, 80	CBCT 5	N	12.0	-	8 × 5
		CBCT 6	LD	2.8	-	
Maxilla and mandible (full)	8, 80	CBCT 7	N	12.0	+	8 × 8
Maxilla	8, 80	CBCT 8	N	12.0	+	8 × 5
Mandible	8, 80	CBCT 9	N	12.0	+	8 × 5
Sinus	8, 80	CBCT 10	N	36.0	-	8 × 14 (stitch)
		CBCT 11	LD	8.5	-	

CBCT: Cone-beam computed tomography; N: Normal; LD: Low dose; FOV: Field of view

WinREMS software was used to read, process, and store the dosimetry data achieved in this study.

After transferring the TLDs to the Physics Research Center of MUMS, the doses absorbed by TLDs, matched to each organ and achieved from the various techniques, were obtained and the intended comparisons were performed.

## Results

In this study, the absorbed doses of the five sensitive organs in the head and neck region including the thyroid gland, the occipital area, the parotid gland, the TMJ and the eyes were measured using the panoramic, Waters, Caldwell and CBCT radiography techniques. The two panoramic imaging techniques revealed the lowest dose for the eyes, but interestingly higher doses for the parotid gland and the occipital area (Table 3).

In total, Waters and Caldwell imaging techniques, as likewise observed in the panoramic technique, indicated that the

occipital area and the parotid gland absorbed a higher dose than other organs (Table 3).

Table 4 summarizes the absorbed dose of organs for CBCT units in this study. In the techniques of CBCT 1-6, 10 and 11, the highest absorbed dose belonged to the parotid gland, occipital area and TMJ. By using the thyroid shield, the thyroid gland had the lowest absorbed dose in the CBCT 8 technique. In the majority of CBCT scans, the parotid region received the highest dose. However, during sinus CBCT (both in low-dose and high-dose modes), the TMJ and eye areas absorbed the highest dose.

## Discussion

The aim of this study was to compare the doses absorbed by a number of sensitive organs within the head and neck region, including the eyes, the thyroid gland, the parotid gland, the TMJ and the occipital area during certain radiography techniques, namely panoramic imaging, Waters, Caldwell and CBCT.

**Table 3.** Absorbed dose of organs in  $\mu\text{Gy}$  in radiographies

Organs	Pan 1	Pan 2	Wat 1	Wat 2	Wat 3	Caldw 1	Caldw 2	Wat 1 + Caldw 1 (A)	Wat 2 + Caldw 2 (B)	Wat 3 + Caldw 2 (C)
Thyroid	198.40	596.02	167.90	170.23	177.97	161.48	245.88	329.38	400.78	408.75
Occipital	820.12	1069.60	151.52	354.14	455.40	272.90	473.67	424.42	1027.64	1129.54
Parotid	2038.62	4187.73	279.32	303.57	339.50	231.85	344.99	511.17	588.96	625.46
TMJ	174.15	289.90	55.65	79.54	131.90	92.90	141.24	148.55	209.61	262.51
Eye	43.10	55.24	130.00	126.00	161.50	124.55	189.71	254.55	338.46	302.96

TMJ: Temporomandibular joint; Pan: Panoramic; Wat: Waters; Caldsw: Caldwell

**Table 4.** Absorbed dose by organs in  $\mu\text{Gy}$  in cone-beam computed tomography (CBCT) radiographs

Organs	CBCT 1	CBCT 2	CBCT 3	CBCT 4	CBCT 5	CBCT 6	CBCT 7*	CBCT 8*	CBCT 9*	CBCT 10	CBCT 11
Thyroid	495.45	285.63	223.93	106.18	533.08	271.05	365.60	199.20	381.82	322.84	212.44
Occipital	1338.68	649.10	1175.53	611.40	641.70	340.95	-	-	-	727.19	273.29
Parotid	2821.45	651.08	2514.45	628.85	930.53	293.53	-	-	-	1287.19	415.04
TMJ	340.10	116.68	284.05	201.80	66.93	47.43	-	-	-	4271.19	817.24
Eye	204.05	28.93	304.30	231.35	220.28	109.33	-	-	-	3799.19	743.19

CBCT: Cone-beam computed tomography; TMJ: Temporomandibular joint

\*In these three radiographs, only the effect of thyroid shield on the absorbed thyroid dose was considered; therefore, the dose absorbed by other organs was not calculated

The highest absorbed dose occurred at the occipital and parotid areas during panoramic, Waters and Caldwell radiography techniques, where the phantom was exposed to radiation at the back of the head. The parotid glands, which are situated along the two lateral axes of rotation, received the highest dose during the panoramic radiography approach. In light of these results, it is fair to say that during the majority of Waters and Caldwell scans, the parotid region absorbed the second-highest dose after the occipital area, possibly because of the beam radiation angle. Among the studied organs, the lowest absorbed dose during panoramic radiography was observed in the eye region, which could be explained by two factors: the focus and the movement of the X-ray tube in the inferior and posterior areas of the head.

The highest increase in the absorbed doses resulting from CBCT was observed in the TMJ and eye regions, compared with the total absorbed dose during Caldwell and Waters techniques. When a shield was used for the thyroid region, the variation of dose reduction ranged from 11% to 28% compared to similar conditions where no shield was used. The average reduction in dose was approximately 22%. Results from all CBCT imaging modes, which were classified according to normal or low-dose resolution and compared pairwise (i.e. CBCT 1 and 2, CBCT 3 and 4, CBCT 5 and 6 and CBCT 10 and 11), pointed out that the absorbed dose of all organs was lower during the low-dose mode.

The study by Pauwels et al.<sup>7</sup> evaluated the effective dose resulted from different CBCT devices using TLDs and anthropomorphic

phantoms. Fourteen different CBCT imaging systems were studied and the results were classified into three groups based on radiation zone. Using the Promax 3D machine at low resolution, the exposure conditions of the present study were almost identical to those of the Pauwels et al.<sup>7</sup> Accordingly, the dose absorbed by the salivary and the thyroid glands were roughly equal in the two studies. However, in the current study, the exposure conditions of the device at normal resolution were nearly half of those in the study of Pauwels et al., and thus the absorbed dose of the thyroid amounted to approximately half of the dose absorbed by this organ in Pauwels et al.'s study.<sup>7</sup>

In the study by Pauwels et al.<sup>7</sup>, the dose absorbed by the thyroid gland was lower than that of the salivary gland for all applied devices. According to the current study, the thyroid gland received a lower dose in comparison with the parotid gland, which can suggest that during CBCT the organs which are not located within the radiation field will only be subject to scattered radiation and will therefore receive considerably lower doses.

The overall conclusion obtained in Pauwels et al.'s study was that, as far as dental practice was concerned, the effective dose resulting from various CBCT devices was higher than that achieved from two-dimensional radiography techniques.<sup>7</sup> The findings of the present study, however, indicated that during all CBCT scans the absorbed dose was not higher than the dose resulting from panoramic, Waters or Caldwell techniques, especially during low-

dose CBCT scans, which delivered a much lower dose in some cases compared to two-dimensional radiographs.

Comparison of the dose absorbed by the TMJ during a pantomography technique using simple films in the study by Christiansen et al.<sup>8</sup> with the dose absorbed by the same organ during a panoramic imaging technique in the present study showed a lower dose of absorption in the latter study (0.17-0.29 mGy in the latter study vs. 0.3-0.4 mGy in the former study). This lower dose could have been caused by the different exposure settings of the devices used, but could also be attributed to factors such as utilizing more advanced devices with higher technology and employing digital receptors in the present study.

In the current study, the highest dose absorbed by TMJ when using CBCT techniques was related to normal resolution sinus CBCT, which was interestingly lower (nearly 12-15 times) compared to the dose received by the same organ during high resolution CT technique in the study by Christiansen et al.<sup>8</sup>

There have been few studies concerned with dosimetry involving Waters and Caldwell radiography. However, in the study by Nadas et al.,<sup>9</sup> the total dose of absorption in sensitive organs during radiographic examination of paranasal sinuses using conventional two-dimensional techniques such as Waters, Caldwell, Lateral and Hirtz was substantially lower than the dose absorbed by organs during high resolution CT. In the present study, the dose absorbed by eyes and TMJ during normal resolution CBCT proved to be higher than the dose these organs absorbed during Waters and Caldwell scans combined.

In the current study, the total dose absorbed by eyes, the thyroid gland and TMJ during Waters and Caldwell scans combined was considerably lower than the total dose these organs were reported to have received during four standard sinus radiography scans (Waters, Caldwell, lateral and Hirtz) in the study by Nadas et al.<sup>9</sup> This seems justifiable when considering the four

standard sinus radiography scans performed in the latter study versus only two radiography scans conducted in the present study. However, a more plausible explanation for this remarkable difference could be based on a number of factors that can lead to a considerable increase in dose, including the fact that the older radiography techniques tended to utilize unsophisticated receptors with relatively lower speed, as opposed to sophisticated high-speed digital receptors currently in use, and that the devices used formerly were not as efficient as the digital devices employed today.

Jadu et al.<sup>10</sup> compared the effective dose obtained during sialography using conventional two-dimensional radiographic techniques versus CBCT. In conclusion, they reported that the effective dose received by submandibular and parotid glands during CBCT at low FOV, mA and kVp settings was not considerably different from the dose resulting from conventional radiography techniques such as panoramic and lateral cephalometric radiography. However, the results of the present study indicated that using the lowest settings of the CBCT machine (mA = 7, kVp = 78 and low-dose resolution), the dose absorbed by the parotid gland turned out to be considerably lower than the corresponding dose when panoramic imaging techniques were employed; and was also approximately equivalent to the total dose received by this organ combining the results of the two techniques of Waters and Caldwell. With regards to the absorbed dose of the parotid gland, the small gap observed in the study by Jadu et al.<sup>10</sup> between the results of CBCT radiography and two-dimensional techniques such as panoramic imaging is likely to have been due to higher exposure conditions of CBCT compared to the current study.

Qu et al.<sup>11</sup> compared the effective radiation dose generated by Promax 3D CBCT machine in various dental protocols. They radiated the beam during different stages marked by changing the device settings: from a minimum

of 8 up to a maximum of 16 mA; using low, normal and high resolutions; and adjusting image size as small (sextants of both jaws), medium (maxilla or mandible) and large (encompassing both jaws). Their results concerning the impact of increasing exposure parameters of the device were consistent with the findings of the present study. Subject to almost identical device settings, the doses absorbed by the thyroid and parotid glands were found to be lower in the present study compared with the study by Qu et al.,<sup>11</sup> which might have been caused by a few factors including possible minor differences in the position of dosimeters, differences in the anthropomorphic phantoms used, and lower exposure conditions in the current study such as lower mA and kVp values.

Hidalgo et al.<sup>5</sup> investigated the effect of using thyroid shields on reducing the absorbed dose of this organ during production of dental CBCT images with high FOV using phantoms. They achieved a dramatic reduction in the dose received by the thyroid gland. Likewise, in the present study, the use of thyroid shields during CBCT 7, 8 and 9 sessions revealed a reduction in the dose absorbed by this organ (22%) compared to CBCT1, 3 and 5 techniques, conducted with same FOV and exposure conditions but without thyroid shields.

In the study by Silva et al.<sup>6</sup> the dose absorbed by all of the studied organs during radiography using i-CAT and NewTom CBCT devices was considerably higher than the dose resulting from panoramic and lateral cephalometric techniques. Such relationship was not observed in the doses absorbed by any of the organs the present study assessed using panoramic imaging and CBCT, while exposure conditions in the two CBCT techniques employed by Silva et al.<sup>6</sup> were much higher than the present study's exposure conditions (kVp = 120 and mA = 23.87 for the i-CAT device and kVp = 110 and mA = 5.4 for the NewTom device) and the power output of their panoramic device was lower than that of the present study.

The relationship observed between the corresponding doses absorbed by the thyroid gland, eyes and the parotid gland using digital panoramic imaging technique (kVp = 67, mA = 5 and t = 8.1) versus CBCT imaging (kVp = 70, mA = 5, t = 7.4) in the study by Garcia Silva et al.<sup>12</sup> was consistent with the findings related to the same organs in the present study which low-dose panoramic imaging and CBCT 1 technique were used (mapping both jaws at low-dose). The mentioned techniques were chosen for the purpose of comparison due to the presence of roughly similar conditions.

The results of the studies by Palomo et al.<sup>13</sup>, Ludlow et al.<sup>14</sup> and Walker and van der Putten<sup>15</sup> which noted the direct influence of, first, decreasing exposure parameters-including radiation area, kVp and mA- on the absorbed dose, and second, observing the ALARA (As Low As Reasonably Achievable) principle on reducing the dose absorbed by patients, were consistent with the findings of the current study.

One study concluded that the use of digital receptors or application of F-speed films instead of D-speed films, besides utilizing rectangular collimation and manipulating exposure settings of the devices can collectively lead to a substantial reduction in the dose received by patients.<sup>14</sup> Similarly, the present study evaluated the effects of different exposure settings as well as the application of thyroid shields on the absorbed dose using modern digital devices and digital receptors.

The present study followed the recommendations set by American Dental Association (ADA) in 2012, including the use of thyroid shields and digital sensors, application of filtration and appropriate exposure conditions (to obtain high-quality images while causing minimal absorbed dose), employment of modern digital devices, etc., in order to investigate the effects of these conditions on the absorbed dose. The aim was to suggest refined guidelines for conducting various radiography techniques



based on the achieved results and in line with the three principles of feasibility, optimization and dose limitation.

### Conclusion

In total, panoramic, Waters and Caldwell imaging techniques indicated that the occipital area and the parotid gland absorbed a higher dose than other organs. In the majority of CBCT scans, the parotid region received the highest dose. CBCT dose varied substantially depending on the device, FOV and selected technique. In CBCT, reducing the height of the FOV and shielding the thyroid are advisable methods and must be implemented to lower the exposure dose. Having acquired the dosimetric data for site-specific imaging using CBCT and

conventional radiography, a future goal is to optimize the exposure parameters that will balance the absorbed dose to the patient. Selection of the most appropriate imaging modality should be performed in view of the absorbed doses, required image quality and the clinical circumstances.

### Conflict of Interests

Authors have no conflict of interest.

### Acknowledgments

This study was made possible by the generous support rendered by the Vice Chancellor for Research of Mashhad University of Medical Sciences, in the form of grant No. 89387 for which the authors are very grateful.

### References

1. Dowsett DJ, Dowsett D, Kenny PA, Johnston RE. The physics of diagnostic imaging. London, UK: Taylor & Francis; 1998. p. 42-8.
2. White SC, Pharoah MJ. Oral radiology-E-Book: Principles and interpretation. 7<sup>th</sup> ed. Philadelphia, PA: Elsevier Health Sciences; 2014. p. 24-6.
3. Budzanowski M, Olko P, Ryba E, Woznicka U. A system for rapid large-area monitoring of gamma dose rates in the environment based on MCP-N (LiF:Mg,Cu,P) TL detectors. Radiat Prot Dosimetry 2002; 101(1-4): 205-9.
4. Gamboa-deBuen I, Buenfil AE, Ruiz CG, Rodriguez-Villafuerte M, Flores A, Brandan ME. Thermoluminescent response and relative efficiency of TLD-100 exposed to low-energy x-rays. Phys Med Biol 1998; 43(8): 2073-83.
5. Hidalgo A, Davies J, Horner K, Theodorakou C. Effectiveness of thyroid gland shielding in dental CBCT using a paediatric anthropomorphic phantom. Dentomaxillofac Radiol 2015; 44(3): 20140285.
6. Silva MA, Wolf U, Heinicke F, Bumann A, Visser H, Hirsch E. Cone-beam computed tomography for routine orthodontic treatment planning: A radiation dose evaluation. Am J Orthod Dentofacial Orthop 2008; 133(5): 640-5.
7. Pauwels R, Beinsberger J, Collaert B, Theodorakou C, Rogers J, Walker A, et al. Effective dose range for dental cone beam computed tomography scanners. Eur J Radiol 2012; 81(2): 267-71.
8. Christiansen EL, Moore RJ, Thompson JR, Hasso AN, Hinshaw DB Jr. Radiation dose in radiography, CT, and arthrography of the temporomandibular joint. AJR Am J Roentgenol 1987; 148(1): 107-9.
9. Nadas S, Duvoisin B, Raimondi S, Schnyder P. Radiation doses delivered to the critical organs during radiological studies of chronic sinusitis. Comparison between TDM and standard radiographies. J Radiol 1994; 75(4): 217-9.
10. Jadu F, Yaffe MJ, Lam EW. A comparative study of the effective radiation doses from cone beam computed tomography and plain radiography for sialography. Dentomaxillofac Radiol 2010; 39(5): 257-63.
11. Qu XM, Li G, Ludlow JB, Zhang ZY, Ma XC. Effective radiation dose of ProMax 3D cone-beam computerized tomography scanner with different dental protocols. Oral Surg Oral Med Oral Pathol Oral Radiol Endod 2010; 110(6): 770-6.
12. Garcia Silva MA, Wolf U, Heinicke F, Grundler K, Visser H, Hirsch E. Effective dosages for recording Veraviewepocs dental panoramic images: Analog film, digital, and panoramic scout for CBCT. Oral Surg Oral Med Oral Pathol Oral Radiol Endod 2008; 106(4): 571-7.
13. Palomo JM, Rao PS, Hans MG. Influence of CBCT exposure conditions on radiation dose. Oral Surg Oral Med Oral Pathol Oral Radiol Endod 2008; 105(6): 773-82.
14. Ludlow JB, Davies-Ludlow LE, White SC. Patient risk related to common dental radiographic examinations: The impact of 2007 International Commission on Radiological Protection recommendations regarding dose calculation. J Am Dent Assoc 2008; 139(9): 1237-43.
15. Walker C, van der Putten W. Patient dosimetry and a novel approach to establishing Diagnostic Reference Levels in dental radiology. Phys Med 2012; 28(1): 7-12.