

Surgical replacement of huge rate of root end amalgam filling with mineral trioxide aggregate angelus: A case report

Alireza Halaj-Mofrad DMD, MSc¹, Masoud Parirokh DMD, MSc²,
Nargessadat Kashi DMD³

Case Report

Abstract

BACKGROUND AND AIM: Surgical endodontics may sometimes fail despite using root-end filling materials (REFMs). In this case report, a symptomatic right maxillary first premolar underwent periradicular surgery (PS) for replacing huge rate of amalgam with mineral trioxide aggregate (MTA).

CASE REPORT: A thirty-year-old healthy woman attended with the chief complaint of recurrent swelling and abscess in the periradicular region of maxillary premolar tooth and sensitivity to percussion. She had a history of PS in the past year. Periapical radiographic images showed a huge rate of amalgam used as REFMs. The PS was performed again and the amalgam was replaced with MTA. Postoperative clinical and radiographic evaluation after 2 years showed no sign of abscess and no sensitivity to percussion and periapical pathosis.

CONCLUSION: In this case report, replacing amalgam with MTA provided reasonable outcome up to 2 years after the treatment.

KEYWORDS: Dental Amalgam; Failure; Mineral Trioxide Aggregate; Root Canal Filling Materials; Root-end Filling

Citation: Halaj-Mofrad A, Parirokh M, Kashi N. **Surgical replacement of huge rate of root end amalgam filling with mineral trioxide aggregate angelus: A case report.** J Oral Health Oral Epidemiol 2018; 7(1): 47-51.

Endodontic periradicular surgery (PS) may be indicated after root canal treatment or retreatment when the orthograde nonsurgical treatment is not possible.¹ In addition to the elimination of pathological tissues, PS consists of resecting apical part of the root (apicoectomy), root-end cavity preparation and placing the root-end filling material (REFM).² A major factor affecting success of PS is using appropriate REFMs to create an effective and long term seal and to prevent the spread of root canal infection to surrounding tissues.^{3,4}

Many dental and medical materials have been used as REFMs; among which, silver amalgam has been the most frequently used material for many years.⁵ Although many

researchers have questioned safety and long term successful outcome of amalgam as a material for root-end filling (REF) in recent years due to the numerous drawbacks of the material like mercury toxicity, corrosion and electrolysis, delayed expansion and developing of tattoos in tissues.⁶

Mineral trioxide aggregate (MTA) has been introduced in 1993 by Torabinejad et al. This material has excellent sealing ability, with the capability of promoting osteoblast activity and lowering toxicity compared with amalgam.⁷ MTA is the most biocompatible REFMs and has an appropriate outcome without any inflammation and mutagenic effect, therefore it can be used for REF.^{8,9} In addition, REFMs has antibacterial and antifungal effect.^{10,11} One of the very

1- Dentist, Private Practice, Kerman, Iran

2- Professor, Endodontology Research Center, Kerman University of Medical Sciences, Kerman, Iran

3- MSc Student, Department of Endodontics, School of Dentistry, Kerman University of Medical Sciences, Kerman, Iran

Correspondence to: Nargessadat Kashi DMD

Email: nargessadat.kashi@gmail.com

important reasons that make MTA a very popular material for REF is formation of cementum on the material.^{4,6,12,13}

In this case report, a symptomatic maxillary premolar in which a huge rate of amalgam was used as the REF in the previous surgery, rate was surgically retreated by replacing amalgam with MTA.

Case Report

A 30-year-old healthy woman referred with a chief complaint of recurrent swelling and abscess in the periradicular region of right maxillary first premolar tooth and sensitivity to percussion (Figure 1).

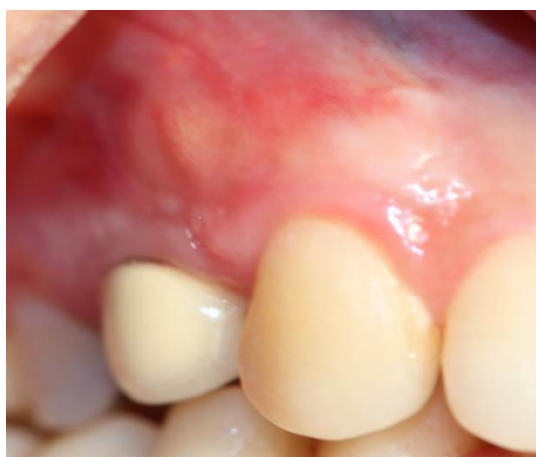

Figure 1. The maxillary right first premolar: Crown on the tooth and periapical abscess

The patient had the opportunity to choose the option of receiving another endodontic surgical treatment or the tooth extraction and single tooth implant placement. The patient had a history of PS in the past year and amalgam was used as a root-end material based on radiographic findings. A cone beam computed tomography (CBCT) was ordered for better evaluation. CBCT images showed a small radiolucency that could be interpreted as a metallic artifact (Figure 2, A-E). Axial view of CBCT did not show presence of a missed root canal (Figure 2, D and E). Furthermore, there were some favorable factors including: normal mobility (maximum grade 1), healthy and compliant patient with no systemic disease. No

periodontal pocket could be observed around the tooth when walking probe was performed. The patients would not like to receive orthograde treatment due to potential of further failure and also need to penetrate through crown for the procedure. The diagnosis of acute apical abscess was made. Therefore, we suggested to repeat the PS and replace the amalgam with MTA.

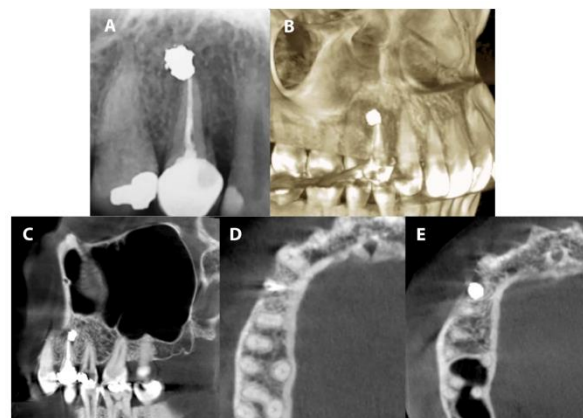


Figure 2. Periapical and cone beam computed tomography (CBCT) images: (A) Periapical radiograph: excess rate of amalgam, (B) 3 dimensional view of CBCT, (C) sagittal view of CBCT (D, E) axial views of CBCT

The PS was started after achieving appropriate anesthesia by 2% lidocaine and 80000 epinephrine (Persocaine, DaruPakhsh, Tehran, Iran). A sulcular full mucoperiosteal flap with one vertical releasing incision in the mesial was used. No buccal plate was present at the apical part of the tooth. In order to remove amalgam without splashing surrounding area, the bone was removed with low speed round bur to access the apical area of the tooth. Amalgam was removed by a curette and a low speed hand piece using copious rate of sterile normal saline (Samen Co., Mashhad, Iran). The root-end was resected as 3 mm due to the potential of crack and accumulation of bacteria at the apical region. A new root-end cavity was prepared by an ultrasonic device (Piezon master surgery, EMS, Nyon, Switzerland) with 3 mm depth MTA Angelus (Angelus, Lorandria, Brazil) and was mixed based on the

manufacturer instruction and placed in root-end cavity. The patient was instructed to use 500 mg amoxicillin every 8 hours for 5 days. The flap then repositioned and sutured carefully. The patient was followed up for 2 years both clinically and radiographically (Figure 3).

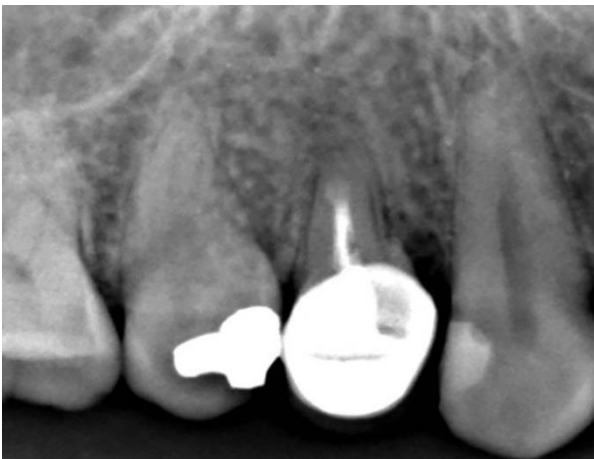

Figure 3. The tooth after replacing amalgam with the mineral trioxide aggregate (MTA) after the 2-year follow up period

The patient's signs and symptoms resolved after one week. The tooth remained asymptomatic until the end of the 2-year follow-up period. There was no sign of abscess or sensitivity to percussion which were the reasons of the patient's first attendance.

Discussion

In this case report, both unsuitable treatment procedure and the bulk of amalgam caused failure of the REF procedure and successful outcome of replacing huge the rate of amalgam with MTA as REF have been presented.

Nonsurgical root canal therapy is a highly predictable option in most cases; dental practitioners may have to perform surgery for teeth with persistent periradicular pathosis despite nonsurgical treatment. PS consists of removing the diseased tissue associated with the root apex, resecting the apical part of the root, cavity preparation in the apical root-end and placing the REFM. The REFMs should seal the root-end cavity and prevent microleakage which is crucial for

endodontic surgery success.²

An ideal material for REF should be biocompatible, osteoinductive, with antibacterial activity, insolubility in tissue fluids, radiopaque, non-toxic, non-corrosive and with suitable handling properties.¹⁴ MTA included most of these specifications.

In the present case, the patient had been offered for two options including either keeping her own tooth by surgical retreatment or extraction and replacing with single tooth implant. The patient decided on keeping her own tooth due to the lower cost, faster function, and the tooth returned aesthetics.¹⁵ The option of retreatment was rejected since the patient was reluctant to receive orthograde treatment.

Amalgam has been used as a REFM for a long time due to the radiopaque, easy to use and non-resorbable characteristics. However, there are many concerns about mercury release from amalgam to bloodstream. Mercury is the most harmful material among the heavy metals with the capability to alternate the distribution and retention of other heavy metals. Mercury is a very reactive metal with numerous toxicity characteristics in high doses including, cerebral ataxia, paresthesia, dysarthria and constriction of the visual fields. According to the results of a study, placing the amalgam as REFM caused high level of blood mercury one week after the treatment, although the mercury levels still was very lower than the toxic level.¹⁴ Drawbacks of amalgam have been discussed in this study and it has been shown that amalgam failures could be healed by replacing amalgam with another bioactive endodontic cement in the apical region.⁵ Today, promising results of bioactive endodontic cements have made them suitable materials for REF.¹⁶

In the present case report, MTA was chosen as the REFM instead of amalgam.

CBCT was ordered to evaluate the causes of symptoms following the previous endodontic surgical treatment. Both American Association of Endodontists (AAE)

and the American Academy of Oral and Maxillofacial Radiology (AAOMR) position statement have recommended to use CBCT for evaluating non-healing teeth that received endodontic treatment.¹⁷ In the present case, according to the CBCT images, the excess rate of amalgam present at the apical part of the treated tooth and possible unsuitable apical seal by the REFM were the causes for failure of the REF treatment rate. Therefore, microleakage and lack of a suitable root-end cavity preparation and filling were assumed to be the causes of the treatment failure.

Recent articles on the advanced endodontic surgery emphasize on using ultrasonic device for root-end cavity preparation and MTA as REFM.¹⁸ The depth of preparation is very important to prevent further communication between the root canal and the periapical tissues. It has been recommended the depth of preparation to be

at least 3 mm.

In this case report, it has been shown that using MTA as REFM could significantly improve the outcome of the endodontic surgery compared to amalgam.

Conclusion

Unsuccessful treatment of periapical surgery can be retreated through performing a second surgery and a suitable root-end cavity preparation hence, REFM could improve the outcome of the treatment.

Conflict of Interests

Authors have no conflict of interest.

Acknowledgments

We would like to thank all members of Endodontology Research Center, Kerman University of Medical Sciences.

References

1. Kourkouta S, Bailey GC. Periradicular regenerative surgery in a maxillary central incisor: 7-year results including cone-beam computed tomography. *J Endod* 2014; 40(7): 1013-9.
2. Favieri A, Campos LC, Burity VH, Santa CM, Abad EC. Use of biomaterials in periradicular surgery: A case report. *J Endod* 2008; 34(4): 490-4.
3. Fernandez-Yanez SA, Leco-Berrocal MI, Martinez-Gonzalez JM. Metaanalysis of filler materials in periapical surgery. *Med Oral Patol Oral Cir Bucal* 2008; 13(3): E180-E185.
4. Asgary S, Eghbal MJ, Ehsani S. Periradicular regeneration after endodontic surgery with calcium-enriched mixture cement in dogs. *J Endod* 2010; 36(5): 837-41.
5. Frank AL, Glick DH, Patterson SS, Weine FS. Long-term evaluation of surgically placed amalgam fillings. *J Endod* 1992; 18(8): 391-8.
6. Baek SH, Plenck H, Jr., Kim S. Periapical tissue responses and cementum regeneration with amalgam, SuperEBA, and MTA as root-end filling materials. *J Endod* 2005; 31(6): 444-9.
7. Baek SH, Lee WC, Setzer FC, Kim S. Periapical bone regeneration after endodontic microsurgery with three different root-end filling materials: amalgam, SuperEBA, and mineral trioxide aggregate. *J Endod* 2010; 36(8): 1323-5.
8. Parirokh M, Torabinejad M. Mineral trioxide aggregate: A comprehensive literature review--Part III: Clinical applications, drawbacks, and mechanism of action. *J Endod* 2010; 36(3): 400-13.
9. Torabinejad M, Parirokh M. Mineral trioxide aggregate: A comprehensive literature review--part II: Leakage and biocompatibility investigations. *J Endod* 2010; 36(2): 190-202.
10. Parirokh M, Torabinejad M. Mineral trioxide aggregate: A comprehensive literature review--Part I: Chemical, physical, and antibacterial properties. *J Endod* 2010; 36(1): 16-27.
11. Bogen G, Kuttler S. Mineral trioxide aggregate obturation: A review and case series. *J Endod* 2009; 35(6): 777-90.
12. Bernabe PF, Holland R, Morandi R, de Souza V, Nery MJ, Otononi Filho JA, et al. Comparative study of MTA and other materials in retrofilling of pulpless dogs' teeth. *Braz Dent J* 2005; 16(2): 149-55.
13. Torabinejad M, Hong CU, Lee SJ, Monsef M, Pitt Ford TR. Investigation of mineral trioxide aggregate for root-end filling in dogs. *J Endod* 1995; 21(12): 603-8.
14. Saatchi M, Shadmehr E, Talebi SM, Nazeri M. A prospective clinical study on blood mercury levels following endodontic root-end surgery with amalgam. *Iran Endod J* 2013; 8(3): 85-8.
15. Parirokh M, Zarifian A, Ghoddsi J. Choice of treatment plan based on root canal therapy versus extraction and implant placement: A mini review. *Iran Endod J* 2015; 10(3): 152-5.

16. Zhou W, Zheng Q, Tan X, Song D, Zhang L, Huang D. Comparison of mineral trioxide aggregate and iRoot BP plus root repair material as root-end filling materials in endodontic microsurgery: A prospective randomized controlled study. *J Endod* 2017; 43(1): 1-6.
17. Special Committee to Revise the Joint AAE/AAOMR Position Statement on use of CBCT in Endodontics. AAE and AAOMR Joint Position Statement: Use of Cone Beam Computed Tomography in Endodontics 2015 Update. *Oral Surg Oral Med Oral Pathol Oral Radiol* 2015; 120(4): 508-12.
18. Tortorici S, Difalco P, Caradonna L, Tete S. Traditional endodontic surgery versus modern technique: a 5-year controlled clinical trial. *J Craniofac Surg* 2014; 25(3): 804-7.