

Systematic review and meta-analysis of diagnostic value of epicutaneous patch testing in patients with oral lichenoid lesions

Zahra Ataei DDS, MD¹, Nader Navabi DDS, MD², Hedayat Mohammadi DDS, MD³,
Raha Habib-Agahi DDS⁴

Review Article

Abstract

BACKGROUND AND AIM: We sought to carry out a systematic review and meta-analysis of the diagnostic value of epicutaneous patch testing in patients with oral lichenoid lesions (OLLs).

METHODS: Bibliographic searches were conducted in electronic databases such as PubMed, the Cochrane library, EBSCO, Scopus, Web of knowledge and Google scholar from January 1990 to December 2011. Search terms related to some or all of the population, intervention, comparison and outcome components (PICO components) were entered into literature databases. Studies were reviewed with respect to inclusion criteria, and data of patient with oral lichenoid reactions, who underwent patch tests, the results of the tests and the healing processes after replacement therapy were reviewed. Data were analyzed by calculating odds ratios (OR) and confidence intervals (CIs) using Stata software program.

RESULTS: 24 studies compared the diagnostic value of patch testing in patients with OLL; 9 studies were included in the meta-analysis. A total of 806 men and women with an age range of 23-84 were evaluated. 16 to 68% of patients had positive patch test results. A total of 443 patients had their restorations replaced, and complete healing ranged from 20 to 93% use expanded form of OLLs at the first time. OR index was 7.8 and 95% CI (3.39-18.38) showed that the chance of recovery of lichenoid lesions in positive patch test patients was 3.4-18.4 times greater than negative patch test patients.

CONCLUSION: Patch test has good diagnostic value in replacing restorative dental materials in patients with OLLs.

KEYWORDS: Amalgam Filling, Lichenoid Lesions, Oral, Meta-Analysis, Patch Test, Systematic Review

Citation: Ataei Z, Navabi N, Mohammadi H, Habib-Agahi R. **Systematic review and meta-analysis of diagnostic value of epicutaneous patch testing in patients with oral lichenoid lesions.** J Oral Health Oral Epidemiol 2015; 4(1): 1-9.

Oral lichenoid lesions (OLLs) are a group of lesions clinically and histologically resembling oral lichen planus, but with different and identifiable etiologies, including chronic graft versus host disease, a range of drugs, systemic lupus erythematosus, chronic ulcerative stomatitis and some dental materials.^{1,2} Amalgam is the most common dental restorative material to elicit a lichenoid lesion that tends to be persistent and only affects the mucosa adjacent to the

amalgam.^{2,3} The major cause of degradation in the oral cavity is through mechanical forces to which restorations are subjected.⁴

The toxic and allergenic potential of mercury and other elements of dental amalgam have received a tremendous amount of attention in recent years. Bolewska et al. reported that in 20 out of 21 (95%) patients with mucosal lesions confined to a contact zone with amalgam substantial accumulations of mercury were visible in both fibroblasts and macrophages. The

1- Associate Professor, Department of Oral Medicine, School of Dentistry, Kerman University of Medical Sciences, Kerman, Iran

2- Assistant Professor, Department of Oral Medicine, School of Dentistry, Kerman University of Medical Sciences, Kerman, Iran

3- Assistant Professor, Department of Oral Medicine, School of Dentistry, Kurdistan University of Medical Sciences, Sanandaj, Iran

4- PhD Student, Department of Dental Materials, Oral and Dental Diseases Research Center, Kerman University of Medical Sciences, Kerman, Iran

Correspondence to: Raha Habib-Agahi DDS

Email: raha2979@yahoo.com

reaction most likely represents a hypersensitivity reaction to mercury.⁵ Clinical studies have shown that replacing dental amalgam restorations with restorations of other materials results in the resolution of OLLs.⁵⁻⁷ The diagnosis of OLLs and the value of the replacements of dental amalgam restorations with respect to patient management are still controversial. Skin patch tests are frequently used to aid in the diagnosis of contact allergies.^{8,9} Studies have shown variable rates of healing of OLLs for patients with positive or negative patch test results^{6,10,11} and controversies still exist on the diagnostic value of the patch test. The aim of this study was to systemically review the literature on the diagnostic value of a patch test for lichenoid lesions and to determine, after meta-analysis, whether this test is helpful or not.

Methods

The review question was defined by the PICO components: population, intervention, comparison and outcomes.¹² Search terms used included MESH (Medical subject headings), AND and OR terms, as follows: Oral lichenoid reaction, oral lichenoid eruption, OLLs, lichen planus, dental amalgam, mercury, contact lesions, patch test, skin test, hypersensitivity, lichen planus AND Oral, Dental restoration AND permanent. Data of electronic databases including the Cochrane library, Scopus, PubMed, EBSCO, Web of knowledge and Google scholar were searched from January 1990 to December 2011. To identify additional studies, reference lists of previously identified published paper were searched. The title and abstract of each article resulting from the literature search were independently reviewed by two investigators, and when the article was considered relevant, the full paper was ordered. Disagreement about eligibility was settled by review of a third reviewer. Inclusion and exclusion criteria for the studies eligible for meta-analysis were as follows:

1. Analytical study design and observational study with a comparison or control group.

2. Diagnosis of OLL based on clinical features and epicutaneous path test result.

3. Duplicate studies (studies originating from the same subjects by the same investigators but published in different journals) were excluded.

4. Articles providing insufficient information to calculate the odds ratio (OR) were excluded.

According to strengthening the reporting of observational studies in epidemiology checklist and using scale-developed numerical methods the selected articles were then appraised. Irrelevant articles based on title, abstract and body texts were excluded. At the end of these steps, there were 24 relevant articles (Figure 1). Their data regarding the location of the studies, patients' characteristics, details of patch test results, number of patients receiving replacement of amalgam restorations, and duration of follow-up and healing were extracted and saved separately for each articles in a file in the Excel software (Microsoft Office 2007). For each study, an OR and 95% confidence interval (CI) was calculated for patients with positive or negative patch test results, who replaced their dental fillings. OR higher than 1 was considered a risk factor and studies with 95% CI including number 1 were not statistically significant. Heterogeneity was measured by calculating I^2 , a statistic for quantifying inconsistency among studies. I^2 index has a range of 0-100%. Values above 50% show significant heterogeneity among studies.¹³

Sub-group analysis was undertaken for the geographical area, patients with OLL and age. Statistical analysis was conducted using Stata software program (version 11, Stata Corp LP, College Station, Texas, USA). Based on the PICO components the search question is the diagnostic value of patch test result in patients with OLL.

Results

In the literature survey, 2082 records were found from 1990-2011. A total of 1375 duplicate records were found and deleted automatically and confirmed manually. Of the remaining 707 articles, 683 irrelevant

articles based on title, abstract and study designs were deleted. Altogether 24 articles were selected for systematic review, and meta-analysis was performed only on 9 studies^{6,14-21} that met the inclusion criteria (Figure 1).

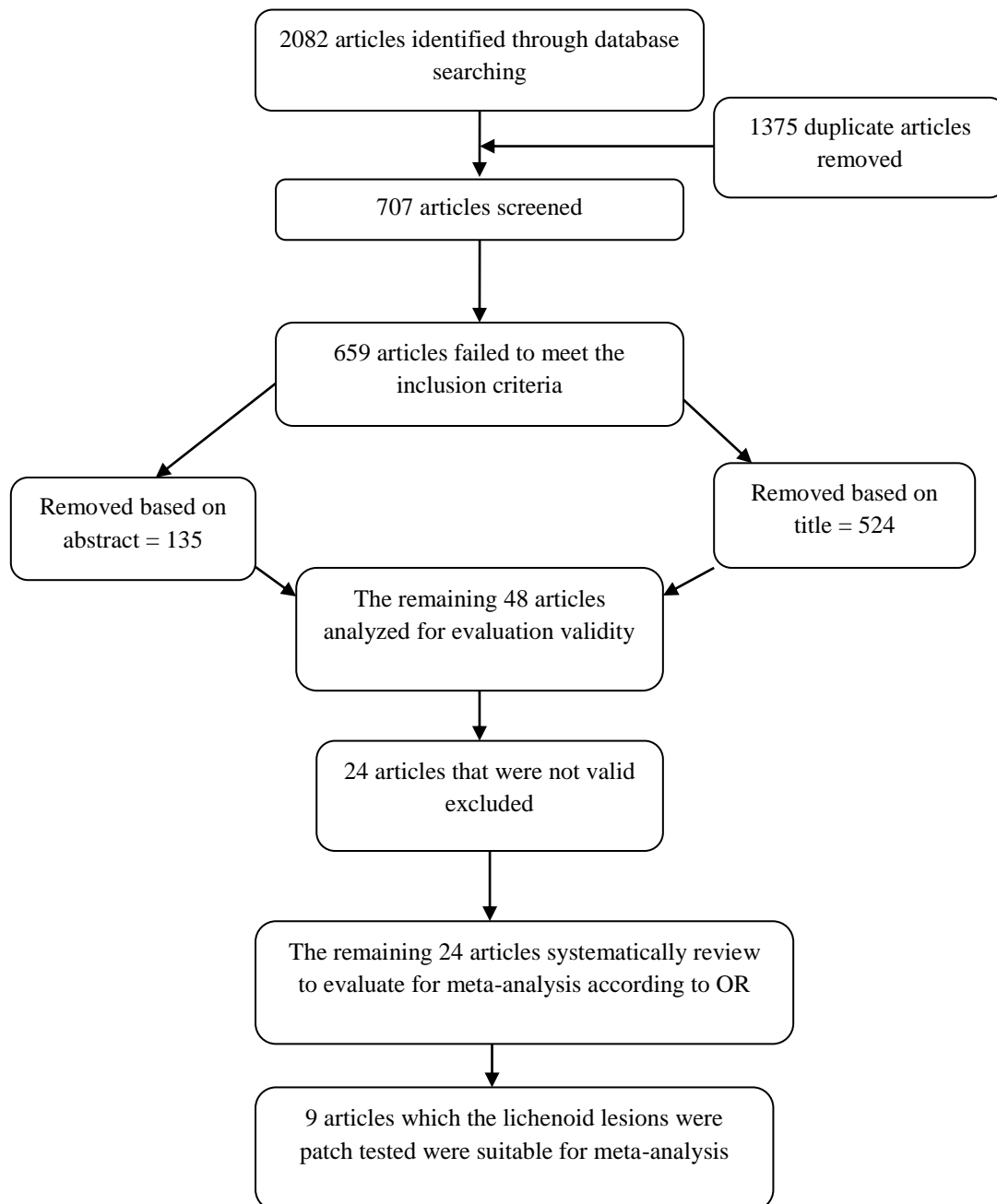


Figure 1. Flow diagram of study
OR: Odds ratio

The studies included a total of 806 patients. Two studies were carried out in Manchester,^{20,21} two in Finland,^{17,18} three in Sweden^{6,14,15} and one in the United Kingdom¹⁶ and one in Australia.¹⁹ The mean age ranged from 23 to 84. In all the studies the number of females was more than males. In general, the majority of lesions were in close contact or in partial contact with amalgam restorations (Table 1).

The clinical diagnosis of OLLs was dependent, in part, on the contact of lichenoid lesions with amalgam. Some studies used topographic relationships as the main indicator,^{17,20} whereas other studies did not report such a relationship clearly.^{14,15} Positive results in the patch test were obtained in 17-68% of patients for at least one component of mercury. However, the delayed reading increased the rate of positive reactions. The minimum time was 24 h^{22,23} and the maximum time was 17 days.^{21,24} A total of 443 out of 806 patients replaced their fillings as a treatment measure. The monitoring period ranged from 1 week²¹ to nine and a half years.¹⁹

The complete recovery range was between 20 and 93%. Improvement occurred within a short time (from 1 week to 3 months) after amalgam filling replacement. In most of the studies, the greatest improvements were found in lesions in direct contact with amalgams.^{6,15,17} The result of χ^2 heterogeneity test in this study was 10.90. I^2 index showed that 26% of the difference between the study results might be attributed to differences and heterogeneity of studies that were included in the meta-analysis. According to DerSimonian and Laird method the variance of τ^2 (Tau) index was 0.47, which confirmed the results of χ^2 and I^2 , indicating that the studies are not heterogeneous ($\chi^2 = 10.90$, $I^2 = 26\%$).¹³ The OR of positive patch test results in patients with OLL, who replaced their fillings, varied between 2.88 (95% CI: 0.30-27, 97) and 84 (95% CI: 6.51-1083.65). The summary estimate OR for all the studies was 7.81 (95% CI: 3.32-18.39)

(Figure 2), showing a statistically significant difference, indicating that the chance of recovery of lichenoid lesions in positive patch test patients replacing dental fillings was at least 3.4 times and at most 18.38 times greater than the negative patch test patients replacing their fillings.

In 9 studies,^{6,14-21} all the patients included had oral lesions (with or without cutaneous lesions). The summary estimate OR was significant in studies by Ibbotson et al.,¹⁶ Laine et al.¹⁸ and Wong and Freeman¹⁹ in Australia and Thornhill et al.²⁰ in Manchester, and was not significant in studies by Skoglund,¹⁴ Henriksson et al.⁶ and Ostman et al.¹⁵ in Sweden (Figure 2). The pooled data of all 9 studies showed that the frequency of OLL was significantly higher in patients with a mean age of 50 years and older ($P < 0.05$).

Discussion

In this systematic review and meta-analysis, we firmly confirm the significant chance of recovery of OLL after amalgam replacement in positive patch test patients. Data showed geographical variability among 24 studies that showed variable prevalence of OLL across the world; however, despite the relatively high prevalence and the significant incidence of OLLs following amalgam restorations, we could not find any evidence of such studies in Africa and Asia. Despite high geographical variety and diversity in different fields, including different elements which were patch tested and different time of patch test evaluation or different substitute materials, according to forest plot, homogeneity of the studies was significant ($I^2 = 26.6\%$) (Figure 2). For example, Lomaga et al.²⁵ used a North American standard antigen series, but Pang and Freeman²⁶ used a European series and Raap et al.²⁷ used a German and Swedish antigen series. However, in all the studies positive patch test results indicated LLs and it showed that type of elements used in patch test had no effect on the results, which is one of the reasons for

Table 1. Description of the reviewed studies

References	Country	Patients (n)	Age (year)	Male/female	Close contact between lesions and restorations	One mercury compound	Complete and marked healing	Follow up (month)	Alternative material used
						Positive patch result (%)	Positive patch result		
Skoglund ¹⁴	Sweden	48 (from 55)	50.4 (31-78)	12/36	33/48	19/48 (39)	18/19	3-36	Gold, composite, porcelain, glass ionomer
Henriksson et al. ⁶	Sweden	159	M = 52.5 and F = 53.1	46/113	108/159	3/17 (17)	NR	36	Gold, composite, porcelain, glass ionomer
Ostman ¹⁵	Sweden	49	52	10/39	30/49	15/30 (50)	14/15	45-72	Gold, full porcelain, PFM, acrylic
Ibbotson et al. ¹⁶	United Kingdom	109 OLLs 22 OLLs + 10 skin LP 66 other lesions	50 51 40	32/77 10/22 25/41	NR	21/109 (19)	17/21	12-24	Composite
Laine et al. ¹⁷	Finland	118	M = 50.4 and F = 49.6	16/102	74/118	80/118 (68)	51/80	6-12	NR
Laine et al. ¹⁸	Finland	19	56.9 (36-79)	5/14	11/19	10/19 (53)	9/10	2-6	NR
Wong and Freeman ¹⁹	Australia	84 (33 PPT, 51 NPT)	57.3 (23-84)	4/29 ppt	All OLL adjusted to amalgam filling	33/84 (39)	31	2 (month) up to 9.5 (years)	Gold, porcelain
Thornhill et al. ²⁰	Manchester	81	54.6	26/60	25/81	NR (23)	26/28	3-12	Gold crown, glass ionomer, PFM composite
Issa et al. ²¹	Manchester	51	53.0	6/45	All OLL adjusted to amalgam filling	21/48 (44)	21/21	1 (week) to 3 (month)	NR

OLL: Oral lichenoid lesions; LP: Lichen planus; M: Male; F: Female; PFM: Porcelain fused to metal; NR: Not recorded; PPT: Positive patch test; NPT: Negative patch test

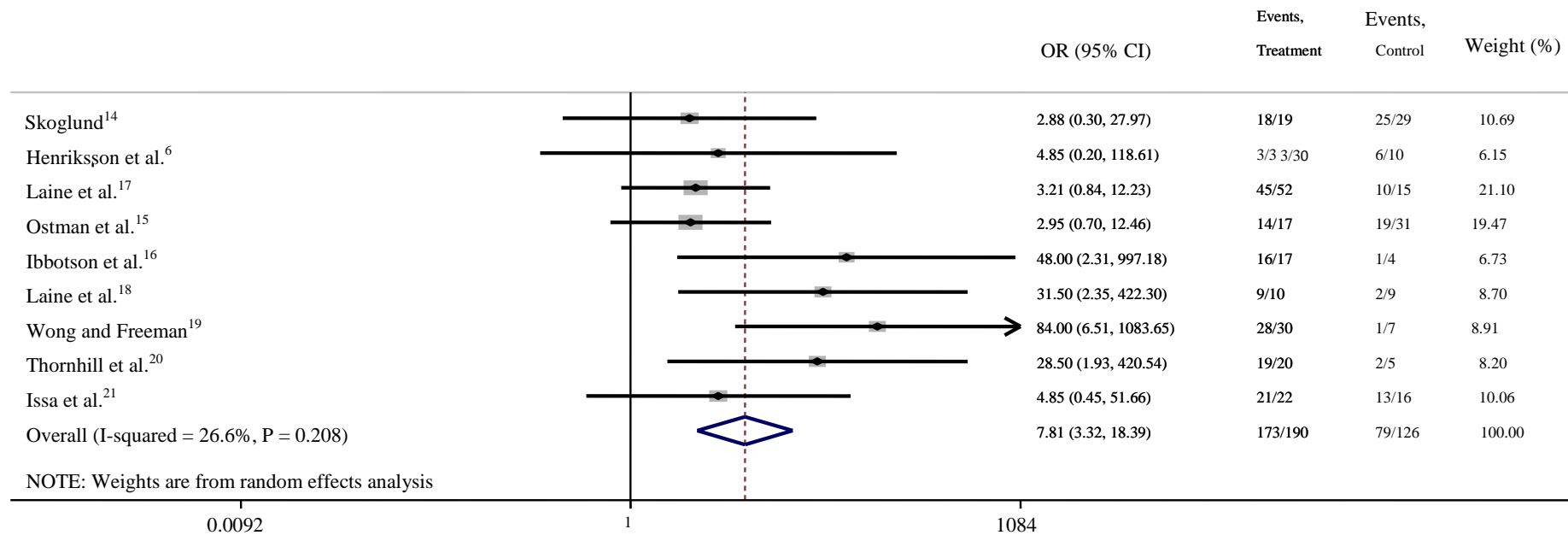


Figure 2. The articles that entered to the meta-analysis

OR: Odds ratio; CI: Confidence interval

homogeneity of these studies. Dunsche et al.²² and Pezelj-Ribaric et al.²³ evaluated the reaction to patch test after 24 h and Yiannias et al.²⁸ and Vammes et al.²⁹ evaluated it after 48 h. The minimum time was for Alanko et al.³⁰ with 24 h and the maximum time was for Koch and Bahmer²⁴ with 17 days. It seems that increasing the duration of patch test evaluation has a direct impact on the results of the research because in some patients late reactions have been observed. Al-Hashimi et al. suggested that interpretations should be collected on the 3rd, 7th and 14th days, or even later in order to avoid delayed reactions.³¹

Different criteria were used to select patients who needed their amalgam restorations replaced: the clinical features, the topographic relationships between amalgam restorations and lesions, and the results of patch tests. Some authors state that partial removal of amalgam fillings may be sufficient to achieve proper recovery.²⁰ However, some studies suggested total removal of fillings for patients with extensive and erosive lesions without amalgam contact.⁶ The percentage of patients who completely recovered ranged from 20¹⁴ to 93%.⁶ The most noticeable recoveries were observed when there was direct contact between the lesion and restoration. The results of this review and meta-analysis showed that replacing amalgam fillings with fillings made of other materials causes these OLLs to disappear or considerably improve within days or weeks.¹⁴ The follow-up period ranged from 1 week 21 to 114 months,¹⁹ which was 3 months or more in all the 9 studies (Table 1).

Studies showed variable rates of healing of OLLs irrespective of the patch test result. Some showed similar rates of healing for patients with positive or negative patch test results,^{6,15} whereas others revealed significant differences between them.³⁰ However, when the available data are taken together, 191/205 (94%) with positive patch tests and 70/137 (51%) with negative results exhibited complete/marked healing of the OLLs (Table 1).

Some studies suggested that the patch test was not useful in determining which patients may benefit from the replacement of amalgam fillings.¹⁴ On the other hand, we found some other studies in which positive results were obtained when fillings were replaced according to the results obtained in the patch test and found a statistically significant difference in the effect of amalgam replacement between patients with positive and negative patch test results.^{6,14} Supporting this theory, Laine et al.¹⁷ divided their patients with OLL into two groups: type I and type II. In type I, the lesions were restricted to amalgam contact areas. In type II, the lesions exceeded amalgam contact area. They found that 78.8% of patients with type I lesions had a positive test for mercury and 44 (out of 47) of these patients either completely recovered or considerably improved after replacing amalgam fillings, which was supported by our study and meta-analysis.

Several studies highlighted the importance of testing a wide range of mercury allergens in their study.^{14,17,32} Laine et al. concluded that the allergen test should include metallic mercury, 1% ammoniated mercury and 0.1% mercury chloride with the aim of detecting all cases of allergy.¹⁷ A recent revision published by Al-Hashimi et al.³¹ on these lesions mentioned that the application of the skin patch test to the suspect material and to any other material which may be used as a substitute might be useful for clinicians, mainly to determine which material would be convenient to replace the lesion-causing materials. Wong and Freeman determined that amalgam replacement is suitable for patients with positive patch tests to mercury.¹⁹ Issa et al. showed that the topographic relation between OLLs and amalgam fillings was a useful marker for prognosis, but it was not a determining indicator of the result.²¹ In the studies by Thornhill et al, the combination of a positive patch test and a strong clinical association between lesions and fillings was

an excellent predictor of lesion recovery after amalgam replacement, and was a better predictor than either the patch test or clinical association alone.²⁰ The proportion of healing of OLL after replacement of dental filling in patients with positive patch test result was higher than patients with negative patch test results.

Various materials were used to replace amalgam fillings, including gold, composite resin, porcelain, glass-ionomer, and acrylic resin that were equally effective and it became clear that inert materials are preferable. Studies investigating the frequency of OLLs among female subjects showed prevalence rates generally higher than expected, independently of the geographical origin, the meta-analysis confuting the hypothesis that a high frequency of OLLs is found in elderly patients (50 years and older) (Table 1).

To avoid publication bias, we decided to include in the meta-analysis only 9 studies in which the patients with lichenoid lesions were patch tested and based on the results, replacement of dental fillings was carried out and recovery of the lesions was evaluated. Diagnosis of OLL is based on detailed history, clinical diagnosis, form of lesion and topographic relationships among the lesions and amalgam restorations.

After carrying out this review and meta-analysis of the different diagnostic criteria proposed for OLLCs, we can conclude that currently the summary estimate OR for all the studies was 7.81 (95% CI: 3.32-18.39) (Figure 2), showing a statistically significant difference which means that the chance of

recovery of lichenoid lesions in positive patch test patients whose dental fillings were replaced was at least 3.4 times and at most 18.38 time greater than negative patch test patients who replaced their fillings. Skin patch test is also preferable prior to an extensive procedure in the oral cavity because of its higher sensitivity and specificity and the fact that the procedure is simpler. In addition, OLLs associated with contact hypersensitivity, especially to dental materials, are a possible risk factor for squamous cell carcinoma; therefore, skin patch test should follow clinical and microscopic examinations.³¹

Conclusion

The meta-analysis showed that the healing chance for replacement therapy in positive patch test patients was higher than negative patch test patients and this difference was significant (OR = 7.81) (95% CI: 3.32-18.39) ($P < 0.05$). Therefore, a positive patch test reaction can be used as an indicator for replacing amalgam restorations. A strong clinical association between lesions and amalgam restorations plus a positive patch test result was a good diagnostic predictor of lesion improvement after amalgam replacement.

Conflict of Interests

Authors have no conflict of interest.

Acknowledgments

This paper has been written from Professional thesis number 47 of Kerman dental school and the authors wish to thank Dr Maryam Rad for her sincere cooperation.

References

1. De Rossi SS, Greenberg MS. Intraoral contact allergy: a literature review and case reports. *J Am Dent Assoc* 1998; 129(10): 1435-41.
2. Ismail SB, Kumar SK, Zain RB. Oral lichen planus and lichenoid reactions: etiopathogenesis, diagnosis, management and malignant transformation. *J Oral Sci* 2007; 49(2): 89-106.
3. Lind PO, Hurlen B, Lyberg T, Aas E. Amalgam-related oral lichenoid reaction. *Scand J Dent Res* 1986; 94(5): 448-51.
4. Gil FJ, Espias A, Sanchez LA, Planell JA. Comparison of the abrasive wear resistance between amalgams, hybrid composite material and different dental cements. *Int Dent J* 1999; 49(6): 337-42.
5. Bolewska J, Holmstrup P, Moller-Madsen B, Kenrad B, Danscher G. Amalgam associated mercury accumulations in

- normal oral mucosa, oral mucosal lesions of lichen planus and contact lesions associated with amalgam. *J Oral Pathol Med* 1990; 19(1): 39-42.
6. Henriksson E, Mattsson U, Hakansson J. Healing of lichenoid reactions following removal of amalgam. A clinical follow-up. *J Clin Periodontol* 1995; 22(4): 287-94.
 7. Mobacken H, Hersle K, Sloberg K, Thilander H. Oral lichen planus: hypersensitivity to dental restoration material. *Contact Dermatitis* 1984; 10(1): 11-5.
 8. Shekar C, Ganesan. Oral lichen planus. *Journal of Dental Sciences & Research* 2011; 2(1): 62-87.
 9. Laine J, Kalimo K, Forssell H, Happonen RP. Resolution of oral lichenoid lesions after replacement of amalgam restorations in patients allergic to mercury compounds. *Br J Dermatol* 1992; 126(1): 10-5.
 10. James J, Ferguson MM, Forsyth A, Tulloch N, Lamey PJ. Oral lichenoid reactions related to mercury sensitivity. *Br J Oral Maxillofac Surg* 1987; 25(6): 474-80.
 11. Lundstrom IM. Incidence of diabetes mellitus in patients with oral lichen planus. *Int J Oral Surg* 1983; 12(3): 147-52.
 12. O'Connor AM, Anderson KM, Goodell CK, Sargeant JM. Conducting systematic reviews of intervention questions I: Writing the review protocol, formulating the question and searching the literature. *Zoonoses Public Health* 2014; 61(Suppl 1): 28-38.
 13. Sutton AJ. *Methods for meta-analysis in medical research*. Hoboken, NJ: John Wiley; 2000.
 14. Skoglund A. Value of epicutaneous patch testing in patients with oral, mucosal lesions of lichenoid character. *Scand J Dent Res* 1994; 102(4): 216-22.
 15. Ostman PO, Anneroth G, Skoglund A. Oral lichen planus lesions in contact with amalgam fillings: a clinical, histologic, and immunohistochemical study. *Scand J Dent Res* 1994; 102(3): 172-9.
 16. Ibbotson SH, Speight EL, Macleod RI, Smart ER, Lawrence CM. The relevance and effect of amalgam replacement in subjects with oral lichenoid reactions. *Br J Dermatol* 1996; 134(3): 420-3.
 17. Laine J, Kalimo K, Happonen RP. Contact allergy to dental restorative materials in patients with oral lichenoid lesions. *Contact Dermatitis* 1997; 36(3): 141-6.
 18. Laine J, Konttinen YT, Beliaev N, Happonen RP. Immunocompetent cells in amalgam-associated oral lichenoid contact lesions. *J Oral Pathol Med* 1999; 28(3): 117-21.
 19. Wong L, Freeman S. Oral lichenoid lesions (OLL) and mercury in amalgam fillings. *Contact Dermatitis* 2003; 48(2): 74-9.
 20. Thornhill MH, Pemberton MN, Simmons RK, Theaker ED. Amalgam-contact hypersensitivity lesions and oral lichen planus. *Oral Surg Oral Med Oral Pathol Oral Radiol Endod* 2003; 95(3): 291-9.
 21. Issa Y, Brunton PA, Duxbury AJ. Effect of amalgam replacement on adjacent lichenoid lesions. *J Dent Res* 2001; 80: 1175.
 22. Dunsche A, Kastel I, Terheyden H, Springer IN, Christophers E, Brasch J. Oral lichenoid reactions associated with amalgam: improvement after amalgam removal. *Br J Dermatol* 2003; 148(1): 70-6.
 23. Pezelj-Ribaric S, Prpic J, Miletic I, Brumini G, Soskic MS, Anic I. Association between oral lichenoid reactions and amalgam restorations. *J Eur Acad Dermatol Venereol* 2008; 22(10): 1163-7.
 24. Koch P, Bahmer FA. Oral lesions and symptoms related to metals used in dental restorations: a clinical, allergological, and histologic study. *J Am Acad Dermatol* 1999; 41(3 Pt 1): 422-30.
 25. Lomaga MA, Polak S, Grushka M, Walsh S. Results of patch testing in patients diagnosed with oral lichen planus. *J Cutan Med Surg* 2009; 13(2): 88-95.
 26. Pang BK, Freeman S. Oral lichenoid lesions caused by allergy to mercury in amalgam fillings. *Contact Dermatitis* 1995; 33(6): 423-7.
 27. Raap U, Stiesch M, Reh H, Kapp A, Werfel T. Investigation of contact allergy to dental metals in 206 patients. *Contact Dermatitis* 2009; 60(6): 339-43.
 28. Yiannias JA, el-Azhary RA, Hand JH, Pakzad SY, Rogers RS, III. Relevant contact sensitivities in patients with the diagnosis of oral lichen planus. *J Am Acad Dermatol* 2000; 42(2 Pt 1): 177-82.
 29. Vamnes JS, Lygre GB, Gronningsaeter AG, Gjerdet NR. Four years of clinical experience with an adverse reaction unit for dental biomaterials. *Community Dent Oral Epidemiol* 2004; 32(2): 150-7.
 30. Alanko K, Kanerva L, Jolanki R, Kannas L, Estlander T. Oral mucosal diseases investigated by patch testing with a dental screening series. *Contact Dermatitis* 1996; 34(4): 263-7.
 31. Al-Hashimi I, Schifter M, Lockhart PB, Wray D, Brennan M, Migliorati CA, et al. Oral lichen planus and oral lichenoid lesions: diagnostic and therapeutic considerations. *Oral Surg Oral Med Oral Pathol Oral Radiol Endod* 2007; 103(Suppl): S25-12.
 32. Rojas-Alcayaga G, Carrasco-Labra A, Danus P, Guzman MA, Morales-Bozo I, Urzua B, et al. Determination of susceptibility to sensitization to dental materials in atopic and non-atopic patients. *Med Oral Patol Oral Cir Bucal* 2012; 17(2): e320-e324.