

## Ameloblastic fibro-odontoma: A case report

Neda Kargahi DDS, MSc<sup>1</sup>, Mahsa Kalantari DDS, MSc<sup>2</sup>,  
Molook Torabi-Parizi DDS, MSc<sup>3</sup>, Parisa Kalantari DDS<sup>4</sup>

### Case Report

#### Abstract

**BACKGROUND AND AIM:** Ameloblastic fibro-odontoma (AFO) is a rare, mixed odontogenic tumor that usually occurs in children and young adults with no gender predominance. Posterior mandibular region is usually involved and a painless swelling is the most common clinical feature.

**CASE REPORT:** We here report a case of AFO in a 12-year-old girl with a complaint of a painful expansive lesion in the right posterior mandible. Radiographic examination showed a well-defined radiolucency containing radiopaque materials. The second molar was displaced by the lesion. Enucleation was conducted and no recurrence was observed after 4 years of follow-up.

**CONCLUSION:** AFO is a benign expansive jaw lesion which develops in children. To treat AFO, proper surgical excision and curettage should be performed.

**KEYWORDS:** Ameloblastic Fibro-Odontoma; Odontogenic Tumors; Neoplasms

**Citation:** Kargahi N, Kalantari M, Torabi-Parizi M, Kalantari P. **Ameloblastic fibro-odontoma: A case report.** *J Oral Health Oral Epidemiol* 2016; 5(3): 166-70.

Ameloblastic fibro-odontoma (AFO) is a rare, benign and mixed odontogenic tumor composed of proliferating odontogenic epithelium in a cellular ectomesenchymal tissue with varying degrees of inductive changes. Clinically, it is usually asymptomatic and might be accompanied by a non-erupted or displaced vital tooth.<sup>1,2</sup> Most cases are diagnosed during the first or second decade of life, with equal frequency in the maxilla and mandible, and no gender predominance.<sup>3,4</sup>

Radiographically, it appears as a well-defined radiolucency containing various amounts of radiopaque material with irregular size and form.<sup>5,6</sup> Histologically, it is composed of strands and islands of odontogenic epithelium embedded in a cell-rich ectomesenchymal tissue, resembling

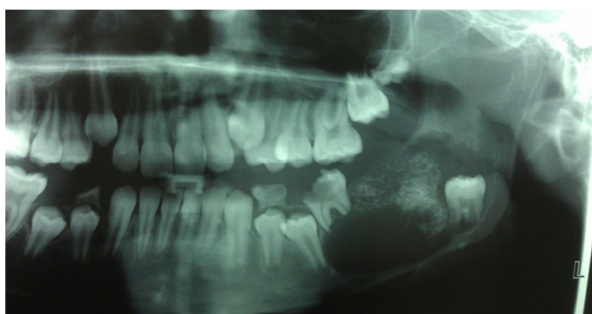
dental papilla. Formation of dental hard tissues resembling enamel and dentin is seen. Usually, AFO is not aggressive and the best treatment is conservative surgical excision and it has no tendency to recur.<sup>7,8</sup> This paper reports a case of a large painful expansive AFO in a 12-year-old girl.

#### Case Report

A 12-year-old girl with a complaint of an expansive and painful lesion in the right posterior mandible was referred to the Department of Oral and Maxillofacial Pathology. Clinical examination showed a swelling in that area with no history of local infection or trauma. The medical and familial histories were unremarkable and the results of physical examination and hematologic tests were within normal limits. Panoramic

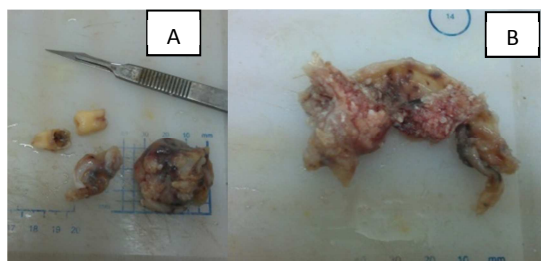
1- Assistant Professor, Department of Oral and Maxillofacial Pathology, School of Dentistry, Isfahan University of Medical Sciences, Isfahan, Iran  
2- Assistant Professor, Oral and Dental Diseases Research Center AND Department of Oral and Maxillofacial Pathology, School of Dentistry, Kerman University of Medical Sciences, Kerman, Iran  
3- Associate Professor, Department of Oral and Maxillofacial Pathology, School of Dentistry, Kerman University of Medical Sciences, Kerman, Iran  
4- Resident, Department of Orthodontics, School of Dentistry, Kerman University of Medical Sciences, Kerman, Iran  
Correspondence to: Mahsa Kalantari DDS, MSc  
Email: kalantary.mahsa@yahoo.com

radiography revealed a well-defined radiolucent lesion containing scattered foci of radiopaque material, extending from the mandibular first molar to the angle of mandible, occupying whole posterior body of the mandible. The roots of the involved first molar were resorbed. The second molar was displaced to the inferior border of the mandible by the lesion (Figure 1).



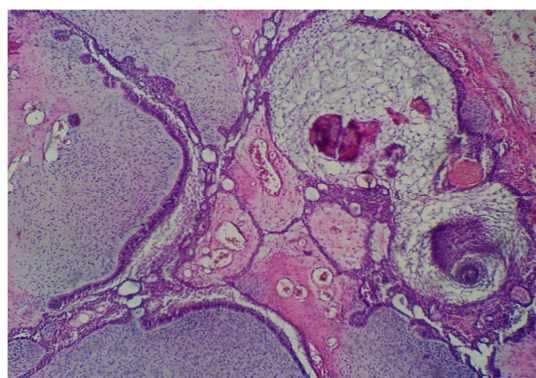
**Figure 1.** Panoramic radiograph showing a well-defined radiolucent lesion which contained scattered foci of radiopaque material in the left lower jaw

Based on the clinical and radiographic findings, the differential diagnosis included several odontogenic cysts and tumors like AFO, immature complex odontoma, calcifying epithelial odontogenic tumor, calcifying odontogenic cyst and odontoameloblastoma. Excisional biopsy was performed and the mass was removed along with the first and second molars. The surgical specimen measured  $3.2 \times 2.7 \times 2$  cm. It had a cystic appearance with a lumen containing a tumor-like mass with mineralized material in its internal wall (Figure 2, A and B).



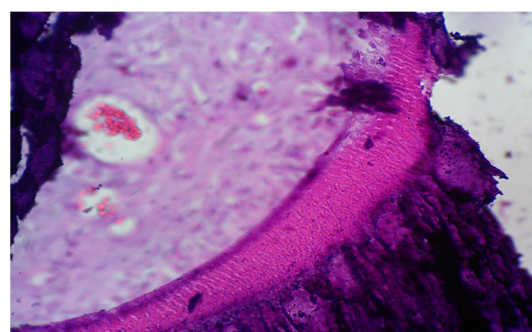
**Figure 2.** Surgical specimen showing a cystic like mass with the first and second mandibular molars (A), internal part of the specimen containing mineralized material (B)

Histopathological examination revealed strands and islands of odontogenic epithelium showing peripheral palisading and loosely arranged cells identical to stellate reticulum in the central area. The stroma comprised of loose connective tissue, with abundant extracellular matrix containing plump fibroblasts resembling the dental papilla (Figure 3). Immature particles similar to dental organ were also seen. Dental hard tissues, including dentinoid structures and osteodentin with ghost cells, were observed in some areas (Figure 4). There was no evidence of malignancy in this lesion. Based on these findings, the tumor was diagnosed as an AFO.



**Figure 3.** The lesion photomicrograph showing strands of odontogenic epithelium with peripheral palisading and stellate reticulum-like area arranging in a myxoid cellular stroma resembling dental papilla

Four years after surgery, no recurrence was observed and the clinical and radiographic appearances of the bone demonstrated bone healing.



**Figure 4.** Photomicrograph showing dentinoid like material

## Discussion

Odontogenic tumors constitute 7% of all cases of oral lesions in children and adolescents.<sup>9</sup> Among them, AFO is relatively rare and represents approximately 1%-3% of all these lesions.<sup>10</sup> A study conducted by Saghravanian et al.<sup>11</sup> in Iran showed that odontogenic tumors constitute 1.9% of oral and maxillofacial lesions and among them, the prevalence of AFO was 3.2%. In similar studies carried out by Kowkabi et al.<sup>12</sup> and Taghavi et al.<sup>13</sup> in Iran, the prevalence of AFO was reported to be 6.5% and 1.6% of odontogenic tumors, respectively.

This lesion usually occurs in people under 20 years of age with an average age of 9 years. Therefore, in the differential diagnosis, age is as an important characteristic parameter.<sup>14,15</sup> Philispen et al.<sup>16</sup> investigated 86 cases of AFO and observed only one case over 20 years of age.

AFO has a marked tendency to occur in the molar area, with an equal distribution between the maxilla and mandible and no gender predilection.<sup>17</sup> Swelling, failure of tooth eruption and tooth displacement are the most common complaints of the patients, but other symptoms, such as pain and paresthesia are not common.<sup>18</sup> Saghravanian et al.<sup>11</sup> noted that painless swelling is the most common clinical finding in patients with AFO. However, the case presented here had a painful swelling in the involved region.

In radiographic evaluation, a well-defined radiolucency containing various amounts of radiopaque material is usually discovered. The amount of radiopaque component differs from one lesion to another; sometimes it predominates and the lesion may resemble an odontoma.<sup>7</sup>

The proper classification of AFO is controversial. According to the World Health Organization, it is included in the group of tumors of odontogenic epithelium with odontogenic ectomesenchyme, a mixed odontogenic tumor. AFO is a benign tumor that exhibits the same benign biologic

behavior as that of ameloblastic fibroma. Conversely, the term odontoameloblastoma (or ameloblastic odontoma) refers to tumors representing a histological combination of ameloblastoma and odontoma.<sup>15</sup>

Recent studies have suggested that the immunohistochemical assays show strong reactivity for amelogenin,  $\beta$ -catenin, and CD44 in odontogenic tumors. In a peripheral AFO case described by Lin et al.,<sup>19</sup> tissue sections showed high levels of amelogenin,  $\beta$ -catenin, CD31 and CD44.

AFO is well-circumscribed and does not invade the surrounding bone. Many authors have reported that AFO can be properly treated by surgical curettage.<sup>2</sup> Nascimento et al.<sup>5</sup> reported the case of an 8-year-old boy with an AFO that was treated by enucleation and curettage, without recurrence during an 8-year follow-up. Also, Arab Oghli<sup>6</sup> followed a case of AFO for six years in a 3.5-year-old boy treated by enucleation and reported no recurrence.

In a study by Tsagaris<sup>20</sup> only one of 29 AFO cases recurred, which was due to inadequate surgical removal at the time of the initial treatment. Also in a case reported by Frissell and Shafer<sup>21</sup> the lesion was aggressive and recurred twice after the initial surgical excision.

Reis et al. have reported that the impacted tooth associated with AFO can be preserved, while others have reported recurrence after preservation of the teeth involved.<sup>22</sup>

Malignant transformation of AFO is rare, and the exact rate is not known.<sup>2</sup> Herzog et al.<sup>23</sup> followed a 14-year-old girl with an AFO for twelve years and during this period, they observed four recurrences with histological changes in the connective tissue toward a more cellular and disorganized pattern diagnosed as odontogenic sarcoma. Also Howell and Burkes<sup>24</sup> presented two cases of malignant transformation of AFOs. They described that malignant transformation of AFO seemed to be more frequent than previously thought. Bregni et al.<sup>25</sup> reported that in patients with a higher average age (33 years), ameloblastic fibro-



sarcomas can developed from previously benign tumors like AFOs.

As mentioned in the literature review, not all AFOs are aggressive, nor should they be expected to recur after conservative surgical excision.<sup>3,6</sup> If recurrence occurs with a change in the histopathological pattern toward a more cellular and unrecognized fibrous stroma with displacement of the epithelial component, then more extensive procedures should be performed.<sup>6</sup>

### Conclusion

AFO is a rare benign neoplasm with low

malignant transformation potential. It seems that a case-dependent treatment plan may result in the best outcome. Therefore, in the case of repeated recurrences or malignant transformations, a more extensive treatment is recommended. Long-term follow-up should be considered in the management of AFO.

### Conflict of Interests

Authors have no conflict of interest.

### Acknowledgments

Authors wish to thank the patient for her corporation.

### References

1. Banihashem Rad SA, Mortazavi H, Eshghpour M, Salehinejad J, Shahakbari R. A large ameloblastic fibro-odontoma of the maxillary sinus. *Iranian Journal of Otorhinolaryngology* 2014; 26(2): 111-4.
2. Nelson BL, Thompson LD. Ameloblastic fibro-odontoma. *Head and Neck Pathol* 2013.
3. De Riu G, Meloni SM, Contini M, Tullio A. Ameloblastic fibro-odontoma. Case report and review of the literature. *J Craniomaxillofac Surg* 2010; 38(2): 141-4.
4. Sassi LM, Stramandinoli BT, Dissenha JL, Zanferrari FL, Schussel JL. Large ameloblastic fibro-odontoma in a 3 yearold child: case report. *RSBO* 2016; 8(1): 114-6.
5. Nascimento JE, Araujo LD, Almeida LY, De Paula AM, Bonan PR. Ameloblastic fibro-odontoma: a conservative surgical approach. *Med Oral Patol Oral Cir Bucal* 2009; 14(12): e654-e657.
6. Arab Oghli A, Scuto I, Ziegler C, Flechtenmacher C, Hofele C. A large ameloblastic fibro-odontoma of the right mandible. *Med oral patol oral cir bucal* 2007; 12(1): 34-7.
7. Gantala R, Gotoor SG, Kumar RV, Munisekhar MS. Ameloblastic fibro-odontoma. *BMJ Case Rep* 2015; 2015.
8. Gantala R, Gotoor SG, Kumar RV, Munisekhar MS. Ameloblastic Fibro-odontome (AFO) of the Mandible: A Case Report. *J Clin Diagn Res* 2014; 8(1): 260-2.
9. Guerrisi M, Piloni MJ, Keszler A. Odontogenic tumors in children and adolescents. A 15-year retrospective study in Argentina. *Med Oral Patol Oral Cir Bucal* 2007; 12(3): E180-E185.
10. Buchner A, Merrell PW, Carpenter WM. Relative frequency of central odontogenic tumors: a study of 1,088 cases from Northern California and comparison to studies from other parts of the world. *J Oral Maxillofac Surg* 2006; 64(9): 1343-52.
11. Saghravanian N, Jafarzadeh H, Bashardoost N, Pahlavan N, Shirinbak I. Odontogenic tumors in an Iranian population: a 30-year evaluation. *J Oral Sci* 2010; 52(3): 391-6.
12. Kowkabi M, Razavi SM, Khosravi N, Navabi AA. Odontogenic tumors in Iran, Isfahan: A study of 260 cases. *Dent Res J (Isfahan)* 2012; 9(6): 725-9.
13. Taghavi N, Rajabi M, Mehrdad L, Sajjadi S. A 10-year retrospective study on odontogenic tumors in Iran. *Indian J Dent Res* 2013; 24(2): 220-4.
14. Lawal AO, Adisa AO, Olusanya AA. Odontogenic tumours: A review of 266 cases. *J Clin Exp Dent* 2013; 5(1): e13-e17.
15. Sekerci AE, Nazlim S, Etoz M, Deniz K, Yasa Y. Odontogenic tumors: a collaborative study of 218 cases diagnosed over 12 years and comprehensive review of the literature. *Med Oral Patol Oral Cir Bucal* 2015; 20(1): e34-e44.
16. Philipsen HP, Reichart PA, Praetorius F. Mixed odontogenic tumours and odontomas. Considerations on interrelationship. Review of the literature and presentation of 134 new cases of odontomas. *Oral Oncol* 1997; 33(2): 86-99.
17. Dolanmaz D, Pampu AA, Kalayci A, Etoz OA, Atici S. An unusual size of ameloblastic fibro-odontoma. *Dentomaxillofac Radiol* 2008; 37(3): 179-82.
18. Surej Kumar LK, Manuel S, Khalam SA, Venugopal K, Sivakumar TT, Issac J. Ameloblastic fibro-odontoma. *Int J Surg Case Rep* 2014; 5(12): 1142-4.
19. Lin YC, Hsu HM, Liu CS, Yuan K. A peripheral ameloblastic fibro-odontoma in a 3-year-old girl: case report, immunohistochemical analysis, and literature review. *Case Rep Dent* 2014; 2014: 321671.

20. Tsagaris GT. A review of the ameloblastic fibro-odontoma [MSc Thesis]. Washington, DC: Washington University; 1972.
21. Frissell CT, Shafer WG. Ameloblastic odontoma; report of a case. *Oral Surg Oral Med Oral Pathol* 1953; 6(9): 1129-33.
22. Reis SR, de Freitas CE, do Espirito Santo AR. Management of ameloblastic fibro-odontoma in a 6-year-old girl preserving the associated impacted permanent tooth. *J Oral Sci* 2007; 49(4): 331-5.
23. Herzog U, Putzke HP, Bienengraber V, Radke C. The ameloblastic fibro-odontoma--an odontogenic mixed tumor progressing into an odontogenic sarcoma. *Dtsch Z Mund Kiefer Gesichtschir* 1991; 15(2): 90-3.
24. Howell RM, Burkes EJ Jr. Malignant transformation of ameloblastic fibro-odontoma to ameloblastic fibrosarcoma. *Oral Surg Oral Med Oral Pathol* 1977; 43(3): 391-401.
25. Bregni RC, Taylor AM, Garcia AM. Ameloblastic fibrosarcoma of the mandible: report of two cases and review of the literature. *J Oral Pathol Med* 2001; 30(5): 316-20.