

Efficacy of closed reduction surgery on treatment of nasal bone fracture in admitted patients to Shahid Bahonar Hospital, Kerman, Iran

Javad Faryabi DDS¹, Ahmad Enhesari MD², Pouyan Sigari DDS³, Shiva Pouradeli MSc⁴

Original Article

Abstract

BACKGROUND AND AIM: Nasal fracture is one of the most common facial fractures and the main goal of this study was evaluation of closed reduction surgery of nasal bone fractures.

METHODS: Thirty six patients including 24 male and 12 female patients suffered from nasal bone fractures were treated by closed reduction method. Preoperative and postoperative computed tomographic scans were analyzed by an expert panel. Statistical methods including chi-square, Fisher's exact test and regression were used to evaluate the relationship between age, sex and type of trauma and to evaluate the efficacy of closed reduction technique.

RESULTS: Type of trauma, age and sex had not any effect on closed reduction efficacy. We had 36.1% complete success rate (nearly complete anatomic reduction), 36.1% favorable success rate (acceptable non-anatomic reduction) and 27.8% absolute failure (no acceptable reduction) after treatment of nasal bone fractures by closed reduction method.

CONCLUSION: Closed nasal reduction is the most commonly used technique for a fractured nose, but it has high degree of failure of treatment, so when choosing the closed reduction method for treatment of nasal bone fractures, appropriate radiography must be taken for meticulous evaluation to reducing the complications.

KEYWORDS: Nasal Fracture; Trauma; Treatment; Bone

Citation: Faryabi J, Enhesari A, Sigari P, Pouradeli S. **Efficacy of closed reduction surgery on treatment of nasal bone fracture in admitted patients to Shahid Bahonar Hospital, Kerman, Iran.** *J Oral Health Oral Epidemiol* 2016; 5(3): 148-53.

Nasal fracture, commonly known as broken nose, is one of the most common facial injuries, since the central position and anterior protrusion of nose from the face makes it a likely target for traumatic injuries.¹⁻⁴ Blunt traumas such as car accidents, sport injuries and fights are the most prevalent causes of nasal fracture.^{3,5,6}

Nasal fractures often include multiple traumas and several models, based on fracture site and force intensity and direction, have been proposed for classification purposes.^{1,6,7} Nasal bone reduction methods include open

reduction and close reduction.⁴ Close reduction treatment is mostly used in the early stages of trauma due to its simplicity and minimal side effects. However, there is a 14% to 50% chance of deformity which may require future septoplasty and rhinoplasty.^{5,8,9}

In addition, some studies have introduced drawbacks of closed reduction. DeFatta et al. concluded that in the closed reduction group of their study, 60% of patients had significant postoperative septal deviation whereas only 12.5% suffered from residual septal deformity in the open reduction group.¹⁰ Besides, in the study of Adami Dehkordi et al., they showed that the

1- Associate Professor, Department of Oral and Maxillofacial Surgery, School of Dentistry AND Oral and Dental Diseases Research Center, Kerman University of Medical Sciences, Kerman, Iran

2- Assistant Professor, Department of Radiology, Shahid Bahonar Hospital, Kerman, Iran

3- Assistant Professor, Department of Oral and Maxillofacial Surgery, School of Dentistry, Ardabil University of Medical Sciences, Ardabil, Iran

4- Epidemiologist, Oral and Dental Disease Research Center AND Kerman Social Determinants on Oral Health Research Center, Kerman University of Medical Sciences, Kerman, Iran

Correspondence to: Javad Faryabi DDS

Email: jfomfs@gmail.com

most symptoms associated with dissatisfaction of patients after closed reduction of nasal bone fractures were nasal hump, septal deviation and dysmorphology of nasal septum.¹¹

Due to the disadvantages of closed reduction of nasal bone fractures, Stafel stated that treatment of acutely fractured nose with an individually tailored protocol of closed reduction, septoplasty, osteotomies, release of the upper lateral cartilages, fracture of the anterior extension of the perpendicular plate of the ethmoid, and camouflaging cartilage grafts yields straighter noses compared to closed reduction alone.⁵

It is necessary to explain that usefulness of conventional (plain) radiographies for clinical decision making is highly controversial and computed tomography (CT) has been shown to be a more accurate diagnostic tool compared to conventional radiography for evaluating nasal bone fractures.¹²⁻¹⁵

So due to greater sensitivity and specificity of CT scan in comparison with conventional radiography and the presence of the above mentioned controversies, we decided to perform this research and investigate the position of the fractured segments with attention to more details by taking pre- and post-operative CT scans and then comparing them together to measure the efficacy of closed reduction for treatment of nasal bone fractures. For meticulous evaluation of closed reduction method, we considered the nearly complete anatomic reduction as complete success of treatment, acceptable non-anatomic reduction as favorable success and no acceptable reduction as absolute failure.

Methods

Patients admitted to Oral and Maxillofacial Ward of Shahid Bahonar Hospital, Kerman, Iran, from 23/8/2014 to 21/3/2015 were enrolled in this study. The inclusion criteria consisted of all patients with isolated nasal bone fractures and the exclusion criteria consisted of patients who had old nasal fractures, open nasal fractures and comminuted nasal fractures. Based

on the inclusion and exclusion criteria, 36 qualified patients were chosen.

First, CT scan of the patients with coronal and axial cuts was obtained (Toshiba Co., Aquilion model, Japan); then, under general anesthesia, closed reduction surgery was done by oral and maxillofacial surgery residents. After stabilization of the patient's general condition in the first day of the surgery, a CT scan with the same machine, same radiology technician and similar conditions of radiation exposure was obtained. CT scans were taken after careful explanation to the patients and an informed written consent form was obtained from each patient.

The study was approved by Vice Deputy of Research at Kerman University of Medical Sciences. For the purpose of this research, all personal information was excluded from both pre-operation and post-operation CT scans and coded stereotypes were presented to expert panel. The expert panel comprised of two oral and maxillofacial surgeons and two radiology specialists who had no information about the patients. Coded stereotypes were analyzed and interpreted by the expert panel and the quality of reduction was reported in terms of complete success rate (nearly complete anatomic reduction), favorable success rate (acceptable non-anatomic reduction) and absolute failure (no acceptable reduction). In cases of complete success, all broken bones were relocated in their anatomic position (Figure 1).

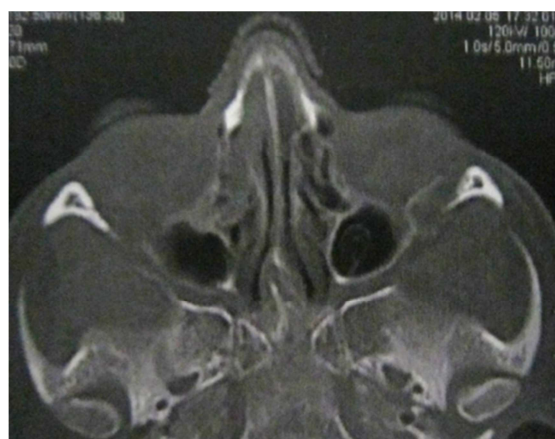

Figure 1. Complete success of closed reduction of a patient with nasal bone fracture

In cases of favorable success, although the original position of bones was missed, most of the broken bones were placed in their pre-traumatic positions (Figure 2).

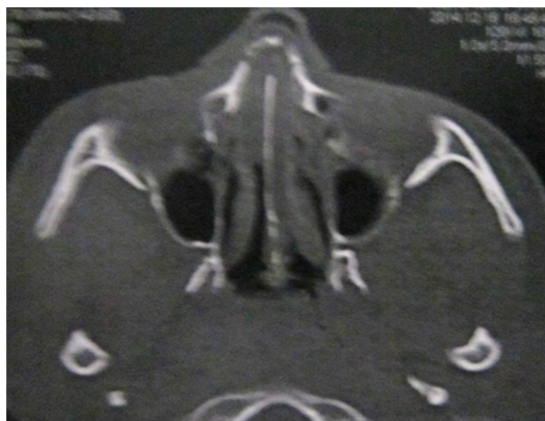


Figure 2. Favorable success of closed reduction of a patient with nasal bone fracture

In cases of absolute failure, the broken bones were completely distant from their original place and close reduction had no significant effect on the complete relocation of bones (Figure 3).

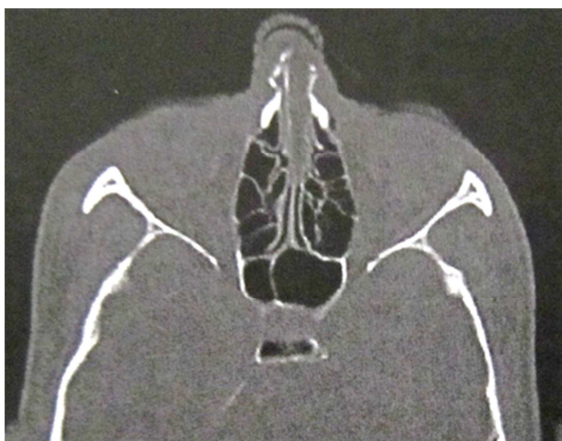


Figure 3. Absolute failure of closed reduction of a patient with nasal bone fracture

Results were analyzed via SPSS software (version 19.0, SPSS Inc., Chicago, IL, USA) using chi-square and logistic regression tests.

Results

This study investigated the data of 36 patients who were admitted in the oral and

Maxillofacial Surgery Ward of Shahid Bahonar Hospital. The patient's age range was between 13-56 years with the average of 29.86 ± 10.5 years. The highest percentage of patients (55.6%) belonged to the age group of 20-30 and the age groups of 10-20 and 50-60 had the lowest number of nasal fracture. Among the 36 patients of the study, 12 were female (33.3%) and 24 were male (66.7%), which shows that the number of male patients were twice as the number of female patients. Causes of nasal trauma in this study consisted of three categories as fights, accidents and falls. Among these, there were 7 cases of fight (19.4%), 26 cases of car accident (72.2%) and 3 cases of fall (8.3%). Based on the type of nasal fracture, 12 patients (33.3%) had unilateral simple fractures, 22 patients (61.1%) showed signs of bilateral simple fractures and 2 patients (5.6%) had bilateral fractures with septum fracture. Among these, the unilateral simple fracture and bilateral fracture with septum fracture, with respectively 61.1% and 5.6%, showed the lowest and highest frequency. Based on treatment effectiveness, 13 cases had complete reduction (36.1%), 13 cases had favorable reduction (36.1%) and 10 cases had absolute failure (27.8%) (Table 1).

Chi-square test was used to study the relationship between treatment effectiveness and age, gender, cause of trauma and type of nasal fracture; however, no significant relationship was identified. This showed that age, gender, cause of trauma and kind of nasal fracture had no impact on the chosen treatment. In terms of treatment effectiveness, there was no significant and meaningful difference between complete success, favorable success and absolute failure treatments. However, classification of treatments into two categories of acceptable reduction (including full and optimal reductions) and unacceptable reduction (including insufficient reduction) showed a significant and meaningful treatment effectiveness ($P = 0.008$).

Table 1. Effectiveness of closed reduction treatment with age, gender, cause of trauma and kind of nasal fracture

| Variables | Categories | Number (%) | P |
|--|-------------------|------------|---------|
| Gender | Female | 12 (33.3) | 0.934 |
| | Male | 24 (66.7) | |
| Age | 10-20 | 3 (8.3) | > 0.999 |
| | 20-30 | 20 (55.6) | |
| | 30-40 | 6 (16.7) | |
| | 40-50 | 4 (11.1) | |
| | 50-60 | 3 (8.3) | |
| Cause of Trauma | Assault | 7 (19.4) | 0.387 |
| | MVA | 26 (72.2) | |
| | Falling down | 3 (8.3) | |
| Type of fracture | Simple unilateral | 12 (33.3) | 0.278 |
| | Simple bilateral | 22 (61.1) | |
| | Septal | 2 (5.6) | |
| Efficacy of closed reduction treatment | Absolute failure | 10 (27.8) | 0.779 |
| | Favorable success | 13 (36.1) | |
| | Complete success | 13 (36.1) | |

MVA: Motor vehicle accident

In addition, multiple logistic regression was used to investigate the impact of this treatment on different individuals and the results showed no significant difference for close reduction method (Table 2).

Table 2. The effect of direct variables on efficacy of closed reduction method of nasal bone fractures

| Variable | B | SE | P |
|---------------|-------|------|------|
| Sex | 0.35 | 1.01 | 0.73 |
| Age | 0.02 | 0.04 | 0.63 |
| Trauma type | -1.30 | 0.94 | 0.16 |
| fracture type | -0.73 | 0.54 | 0.18 |

* Multiple logistic regression

Discussion

According to the results of this study, if absolute success in reduction of nasal bone fracture was considered as the optimum treatment, then the closed reduction procedures would not be a sufficient and

suitable treatment for most cases of nasal bone fractures. Our finding is compatible with research done by DeFatta et al. that stated in the closed reduction group of their patients, 60% had significant postoperative septal deviation.¹⁰ In addition, Staffel stated that acute fractures yielded straighter noses with an individually tailored protocol of closed reduction, septoplasty, osteotomies, release of the upper lateral cartilages, fracture of the anterior extension of the perpendicular plate of the ethmoid, and camouflaging cartilage grafts compared to treatment by closed reduction alone.⁵ Adami Dehkordi and et al. have shown that the most dissatisfaction of their patients belonged to closed reduction group of nasal bone fractures with symptoms like nasal hump, obstruction of nose, deviated nose, and dysmorphism of nasal septum.¹¹

In this study, nasal fractures of male patients were twice as female patients which

is in concordance with studies of Murray et al.³ and Ashoor and Alkhars.¹⁶

In the present study, the highest rate of nasal fracture was observed among the age group of 20-30 years (55.6%) and the lowest prevalence was observed in age groups of 10-20 years (8.3%) and 50-60 years (8.3%) that is compatible with the study of Cavalcanti and Melo that demonstrated 13-17-year-old teenagers had the highest rate of fractures¹⁷ and with Hwang et al. study that showed the highest incidence of nasal fractures was among the age group of 11-20 years.¹²

In this study, 61.1% of the patients had simple (without comminution) bilateral fractures, while 33.3% had simple one-sided fractures and 5.6% showed signs of bilateral fractures with nasal septum fracture. Since most septum fractures require open reduction or septoplasty treatment, were excluded these patients from our study which yielded to low prevalence of septum fracture.

There was no significant relationship between the effectiveness of close reduction treatment and age, gender, cause of trauma and type of nasal fracture.

In overall view, closed reduction of nasal bone fractures is an easy procedure performed routinely for treatment of this type of nasal fractures, but the failure of this method is

relatively high, and therefore we recommend that every patient suffering from nasal bone fractures must be evaluated individually by thorough clinical and radiographic examination and by taking appropriate CT scan if needed before attempting closed reduction techniques. If the operator has doubt for efficacy of closed reduction method, then it is advised to do open reduction surgery instead to minimize future complications.

Conclusion

We must cautiously use closed reduction method for treatment of nasal bone fractures in selected patients, not routinely. Clinical and radiographic examination especially CT scan should be performed when deciding between closed versus open reduction for treatment of nasal bone fractures.

Conflict of Interests

Authors have no conflict of interest.

Acknowledgments

The authors would like to express their gratitude to the Vice Deputy of Research at Kerman University of Medical Sciences, Iran, for their financial support of the study and also from all patients for their participant in this study.

References

1. Reddy LV. Nasal fractures. In: Fonseca RJ, Marciani RD, Turvey TA, Editors. Oral and maxillofacial surgery: Anesthesia and pain control, dentoalveolar surgery, practice management implant surgery. 2nd ed. Philadelphia, PA: Saunders/Elsevier; 2009. p. 270-82.
2. Rhee SC, Kim YK, Cha JH, Kang SR, Park HS. Septal fracture in simple nasal bone fracture. *Plast Reconstr Surg* 2004; 113(1): 45-52.
3. Murray JA, Maran AG, Mackenzie II, Raab G. Open v closed reduction of the fractured nose. *Arch Otolaryngol* 1984; 110(12): 797-802.
4. Mondin V, Rinaldo A, Ferlito A. Management of nasal bone fractures. *Am J Otolaryngol* 2005; 26(3): 181-5.
5. Staffel JG. Optimizing treatment of nasal fractures. *Laryngoscope* 2002; 112(10): 1709-19.
6. Logan M, O'Driscoll K, Masterson J. The utility of nasal bone radiographs in nasal trauma. *Clin Radiol* 1994; 49(3): 192-4.
7. Sharon Arnovich BJ, Costello BJ. Nasal fractures: Evaluation and management. In: Fonseca RJ, Barber HD, Powers MP, Frost DE, Editors. Oral and maxillofacial trauma. 4th ed. Philadelphia, PA: Elsevier Health Sciences; 2013. p. 491-505.
8. Bremke M, Wiegand S, Sesterhenn AM, Eken M, Bien S, Werner JA. Digital volume tomography in the diagnosis of nasal bone fractures. *Rhinology* 2009; 47(2): 126-31.
9. Yabe T, Ozawa T, Sakamoto M, Ishii M. Pre-and postoperative x-ray and computed tomography evaluation in acute nasal fracture. *Ann Plast Surg* 2004; 53(6): 547-53.

10. DeFatta RJ, Ducic Y, Adelson RT, Sabatini PR. Comparison of closed reduction alone versus primary open repair of acute nasoseptal fractures. *J Otolaryngol Head Neck Surg* 2008; 37(4): 502-6.
11. Adami Dehkordi M, Eynalghozati S, Sharifi Daloe SM, Safaie Yazdi N, Ghasem SM, Mehrpour M. The association between nasal fracture treatment outcome and its causes in Mashhad Farabi hospital. *J Birjand Univ Med Sci* 2011; 18(3): 217-24. [In Persian].
12. Hwang K, You SH, Kim SG, Lee SI. Analysis of nasal bone fractures; a six-year study of 503 patients. *J Craniofac Surg* 2006; 17(2): 261-4.
13. Gurkov R, Clevert D, Krause E. Sonography versus plain x rays in diagnosis of nasal fractures. *Am J Rhinol* 2008; 22(6): 613-6.
14. Baek HJ, Kim DW, Ryu JH, Lee YJ. Identification of nasal bone fractures on conventional radiography and facial CT: Comparison of the diagnostic accuracy in different imaging modalities and analysis of interobserver reliability. *Iran J Radiol* 2013; 10(3): 140-7.
15. Lee IS, Lee JH, Woo CK, Kim HJ, Sol YL, Song JW, et al. Ultrasonography in the diagnosis of nasal bone fractures: a comparison with conventional radiography and computed tomography. *Eur Arch Otorhinolaryngol* 2016; 273(2): 413-8.
16. Ashoor AJ, Alkhars FA. Nasal bone fracture. *Saudi Med J* 2000; 21(5): 471-4.
17. Cavalcanti AL, Melo TR. Facial and oral injuries in Brazilian children aged 5-17 years: 5-year review. *Eur Arch Paediatr Dent* 2008; 9(2): 102-4.