

Prevalence and complications of ectopic eruption in 6-12-year-old children based on radiographic evaluation

Deniz Sila Ozdemir PhD¹, [Esra Hato](#)², Yunus Emre Kuyucu PhD³, Halenur Altan PhD⁴

Original Article

Abstract

BACKGROUND AND AIM: This study aimed to retrospectively determine the prevalence of ectopic eruption observed in permanent teeth during the mixed dentition period and the complications caused by it, based on radiographic findings.

METHODS: This study included children aged 6-12 years admitted to the Department of Pediatric Dentistry, Tokat Gaziosmanpaşa University. The orthopantomographic radiographs of 2664 patients were used to examine anterior and premolar teeth by two different researchers. The patient's age and gender, the teeth with ectopic eruption, and complications caused by it on the jaw, adjacent teeth, and arch were recorded.

RESULTS: Ectopic eruption was observed in 176 patients (91 girls and 85 boys) out of 2664 patients included in the study and the prevalence rate was 6.6%. The eruption complications were observed in 131 of 176 patients with ectopic eruption (4.9%). Among the complications, the most common and the least common complications were the reduction in the arch length (1.2%) and the impaction of the adjacent permanent tooth (0.1%), respectively. The ectopic eruption was mostly common in premolar teeth.

CONCLUSION: The early radiographic diagnosis of ectopic eruption can lead to more manageable and more acceptable methods of treatment with no need to adopt complicated treatments in appropriate cases, providing a great advantage for both the patient and the dentist.

KEYWORDS: Ectopic Eruption; Prevalence; Complicity; Early Diagnosis

Citation: Ozdemir DS, Hato E, Kuyucu YE, Altan H. **Prevalence and complications of ectopic eruption in 6-12-year-old children based on radiographic evaluation.** J Oral Health Oral Epidemiol 2022; 11(1): 25-31.



This is an open-access article distributed under the terms of the [Creative Commons Attribution Unported License](#), which permits unrestricted use, distribution, and reproduction in any medium, provided the original work is properly cited.

Ectopic eruption is malposition of permanent teeth which affects both primary and permanent teeth due to growth failure in the jaw or jaw segment and may cause premature loss.¹ While ectopic eruption is mostly observed in the maxillary first permanent molars and canines, it is least common in the mandibular canine, mandibular second premolars, and maxillary lateral incisors. It was reported that ectopic eruption of canine teeth occurred in 1.5%-2.0% of the population and was two times more common in males.² The prevalence of the second molars' ectopic eruption was 0.2-0.3%.³

The etiology of ectopic eruption is not known precisely as the multifactorial growth and development process makes it difficult to identify the specific primary etiological factors of ectopic eruption.⁴ The factors that cause ectopic eruption include the dislocations during the formation phase of permanent tooth germs, bone-tooth size mismatches, or ankylosis of primary teeth and supernumerary teeth.² The most common reasons for the etiology of ectopic eruption of permanent incisors are odontoma, cysts, supernumerary teeth, and crown-root malformations due to trauma to the primary teeth.^{5,6}

1- Assistant Professor, Department of Pediatric Dentistry, Faculty of Dentistry, Abant İzzet Baysal University, Bolu, Turkey

2- Research Assistant, Department of Pediatric Dentistry, Faculty of Dentistry, Tokat Gaziosmanpaşa University, Tokat, Turkey

3- Assistant Professor, Department of Biostatistics, Faculty of Medicine, Tokat Gaziosmanpaşa University, Tokat, Turkey

4- Associate Professor, Department of Pediatric Dentistry, Faculty of Dentistry, Necmettin Erbakan University, Konya, Turkey

Address for correspondence: Esra Hato; Research Assistant, Department of Pediatric Dentistry, Faculty of Dentistry, Tokat Gaziosmanpaşa University, Tokat, Turkey; Email: esrahato@gmail.com

Dentists should be aware of the potential sequence of ectopic eruption and the available treatment options. Early diagnosis always provides advantages. The early loss of the affected primary tooth due to ectopically erupted teeth and accordingly, the tipping of adjacent teeth into the cavity may reduce the arch length and impaction.^{7,8} These problems may affect the need and duration of orthodontic treatment. In ectopic impaction cases, the eruption can be helped by promoting the eruption process or the eruption pathway can be created surgically.

After early diagnosis and comprehensive evaluation of the teeth with ectopic eruption, it is essential to make appropriate treatment planning to reduce the need for long-term and costly treatments that may be required afterward. This study aimed to retrospectively determine the prevalence of ectopic eruption observed in permanent teeth during the mixed dentition period and the complications caused by it based on the radiographic findings.

Methods

Study model: The protocol of this study was approved by the Clinical Research Ethics Committee, Tokat Gaziosmanpaşa University (20-KAEK-075). Informed consent was not obtained since it was a retrospective study. Considering the possible losses in the sample size determined based on the study by Bondemark and Tsiopa⁹ and on the basis of the following formula, 50% was added as a reserve and the sample size was determined as 2664. This study included children aged 6-12 years who were admitted to the Department of Pediatric Dentistry, Tokat Gaziosmanpaşa University. The orthopantomographic radiographs of 2664 patients were used to examine anterior and premolar teeth by two different researchers (pediatric dentists). The patients' age and gender, teeth with ectopic eruption, and complications caused by it on the jaw, adjacent teeth, and arch were recorded.

$$n = \frac{(z^2)P(1-P)}{d^2} \quad 'z=1.96, p=0.02, d=0.05'$$

where n is the sample size, Z is Z statistic for the level of confidence, P is expected prevalence, and D is allowable error.

Panoramic imaging: No radiographs were explicitly obtained for this study and pre-existing digital panoramic radiographs in patients' records were used.

The radiographs taken with the same dental panoramic device (Soredex, Tuusula, Finland) were included in the study. The radiography was routinely performed by placing the patients on the dental panoramic machine, with the machine's vertical line parallel to the patient's sagittal plane and the horizontal line (Frankfort plane) parallel to the floor.

Evaluation of radiographs: Based on the classification of ectopic eruption of permanent first molars described by Barberia-Leache et al.,¹⁰ the ectopic eruptions observed in anterior and premolar teeth were detected. Two researchers determined the complications observed in the teeth radiographs with ectopic eruptions. Based on the complications indicated in the literature, the complications caused by the teeth with an ectopic eruption in the adjacent teeth and on the arch were grouped and the prevalence was investigated. These complications were classified as a reduction in the arch size, impaction of the tooth, asymmetric root resorption in the associated primary tooth (only distal or only mesial root resorption), delay in eruption, resorption in the adjacent tooth root, and the impaction of the adjacent permanent tooth.^{9,11} The teeth with ectopic eruption were categorized according to whether they presented one or more of these complications in their current position or did not cause any complications.

The statistical analysis included cross-tables with descriptive statistics, frequencies, and the chi-square analysis. When P values were below 0.050, the result was considered statistically significant. The calculations were performed using the SPSS software (version 22, IBM Corporation, Armonk, NY, USA).

Results

The ectopic eruption was observed in 176 patients (91 girls and 85 boys) of 2664 patients

included in the study and the prevalence was 6.6%. The inter-rater reliability coefficient of the study was 0.820. In this case, the data were found to be "highly reliable" since they were within the range of $0.60 \leq \alpha \leq 0.90$.

The eruption complications were observed in 131 of 176 patients with ectopic eruption (prevalence as 4.9%). Concerning the distribution of ectopic eruption by gender, the ectopic eruption was more common in the girls (51.7%) compared to the boys (48.3%); however, it was not statistically significant ($\chi^2 = 0.749$, $P = 0.387$) (Table 1).

When the prevalence of ectopic eruption was examined in the anterior and premolar regions, it was higher in the premolar region than in the anterior region. In the premolar region, the ectopic eruption was mostly observed in the lower left second premolar with a prevalence of 1.38%. In the anterior region, the ectopic eruption was mostly observed in the right upper canine tooth with a prevalence of 0.3% (Table 2).

Complications were observed in 4.9% of the patients, with the most common complication being the reduction in the arch length (1.2%) (Figure 1) and the second most common one being the delay in eruption (1.0%) (Figure 2). The least common complication was the impaction of the adjacent permanent tooth (0.1%). While the most common complication among the girls was

the impaction of the teeth, the most common complication among the boys was the reduction in the arch length. No statistically significant difference was found in complications between the boys and girls (Table 1).

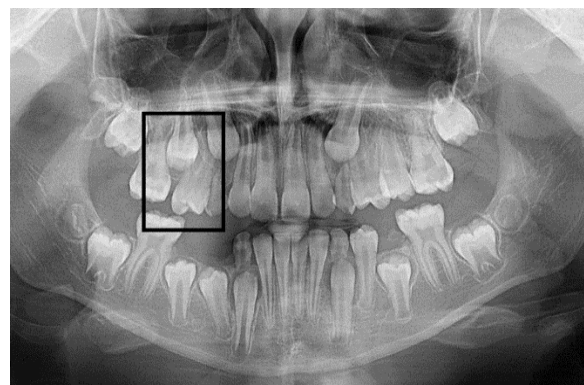


Figure 1. Reduction in the arch length in the upper jaw and the impacted adjacent tooth (tooth number 15) as a result of the ectopic eruption of tooth number 14

It was observed that the most common types of complications observed in the lower left second premolar, where complications were mostly observed in the premolar region, were asymmetric root (distal) resorption in the associated primary teeth (32.4%), tooth impaction (18.9%), arch length reduction (16.2%), and asymmetric root (mesial) resorption in the associated primary teeth (13.5%), respectively.

Table 1. Complication distribution by gender

Complications types		Gender		χ^2	P
		Girl [n (%)]	Boy [n (%)]		
Ectopic	No	1202 (48.3)	1285 (51.7)	0.749	0.387
	Yes	91 (51.7)	85 (48.3)		
Reduction in the arch length	No	1279 (48.6)	1354 (51.4)	0.039	0.843
	Yes	14 (45.2)	17 (54.8)		
Impaction of the teeth	No	1277 (48.4)	1363 (51.6)	2.497	0.114
	Yes	16 (66.7)	8 (33.3)		
Asymmetric root (mesial) resorption in the associated primary teeth	No	1283 (48.4)	1367 (51.6)	2.103	0.147
	Yes	10 (71.4)	4 (28.6)		
Asymmetric root (distal) resorption in the associated primary teeth	No	1282 (48.5)	1360 (51.5)	0.001	0.999
	Yes	11 (50.0)	11 (50.0)		
Delay in eruption	No	1280 (48.5)	1358 (51.5)	0.023	0.881
	Yes	13 (50.0)	13 (50.0)		
Resorption in the neighboring tooth root	No	1284 (48.5)	1362 (51.5)	0.016	0.901
	Yes	9 (50.0)	9 (50.0)		
Impaction of the adjacent permanent tooth	No	1293 (48.6)	1370 (51.4)	-	0.999*
	Yes	1 (50.0)	1 (50.0)		

*P value is significant at the 0.05 level.

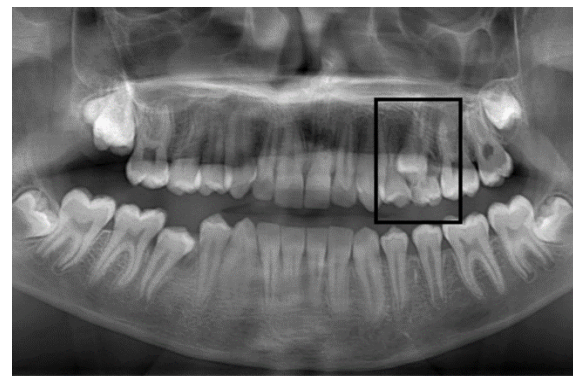
Table 2. Distribution of Ectopic Eruptions by Teeth

Tooth number and area	n (%)
12	1 (0.6)
13	8 (4.5)
21	3 (1.7)
23	7 (4.0)
33	4 (2.3)
43	2 (1.1)
14	12 (6.8)
15	19 (10.8)
24	13 (7.4)
25	14 (8.0)
35	37 (21.0)
34	14 (8.0)
44	11 (6.3)
45	31 (17.6)
Anterior	25 (14.2)
Premolar	151 (85.8)

It was shown that the most common complication observed in the right lower second premolar, where the second most common complication was mostly observed in the premolar region, was the asymmetric root (distal) resorption in the associated primary teeth (22.6%). In the anterior region, it was noticed that the impaction of the tooth (50.0%) was the most common complication in the right upper canine tooth.

Tooth impaction was observed more in the premolar region compared to the anterior region and a statistically significant difference was found ($P = 0.002$). Similarly, the delay in the eruption was observed more in the premolar region than in the anterior region

and the difference was statistically significant ($P = 0.001$) (Table 3).

**Figure 2.** Delay in eruption due to ectopic eruption of tooth number 25

Discussion

The ideal tooth eruption is possible only when the tooth bud is in a normal position, there is no obstruction in the eruption path, and there is an intact dental follicle/periodontal ligament (PDL).¹² When one or more of these factors are defective, eruption disorder may occur and the abnormal eruption direction of the dental germ may lead to undesirable complications on itself and the adjacent teeth.¹² In the present study, the prevalence of anterior and premolar teeth eruption and the complications due to ectopic eruption were examined. There was no study in the literature examining the ectopic eruption of anterior and premolar teeth and the complications due to ectopic eruption.

Table 3. Distribution of complications by tooth area

Complications types		Tooth area		P
		Anterior [n (%)]	Premolar [n (%)]	
Reduction in the arch length	No	20 (13.8)	125 (86.2)	0.777 [#]
	Yes	5 (16.1)	26 (83.9)	
Impaction of the teeth	No	16 (10.5)	136 (89.5)	0.002 [*]
	Yes	9 (37.5)	15 (62.5)	
Asymmetric root (mesial) resorption in the associated primary teeth	No	25 (15.4)	137 (84.6)	0.224
	Yes	-	14 (100)	
Asymmetric root (distal) resorption in the associated primary teeth	No	25 (16.2)	129 (83.8)	0.047 [*]
	Yes	-	22 (100)	
Delay in eruption	No	15 (10.0)	135 (90.0)	0.001 [*]
	Yes	10 (38.5)	16 (61.5)	
Resorption in the neighboring tooth root	No	25 (15.8)	133 (84.2)	0.080
	Yes	-	18 (100)	
Impaction of the adjacent permanent tooth	No	25 (14.4)	149 (85.6)	0.999 [#]
	Yes	-	2 (100)	

*P value is significant at the 0.05 level (Chi-square test), [#]Fisher Exact

The ectopic eruption of maxillary permanent first molars has been examined mainly. Therefore, the present study will make a significant contribution to the literature with this aspect.

In the literature, the prevalence of ectopic eruption of maxillary permanent first molars varies from 0.75 to 6.00%.^{9,13,14} The prevalence of ectopic eruption of canine teeth is between 1.5% and 2.0%.² In the present study, while the prevalence of ectopic eruption in the anterior and premolar teeth was 6.60%, the prevalence of canine teeth's ectopic eruption was 0.8%. It was considered that the lower prevalence of canine teeth compared to the literature was affected by the inclusion of radiographs of patients up to 12 years old in the study, only examining the radiography of dental eruptions, and failure to follow up clinically.

In the literature, it was reported that the ectopic eruption of permanent incisor, canine, premolar, and permanent first molars was the most common cause of the reduction in the arch length.^{1,10,13} Furthermore, it was indicated that in cases where the buccal bone was resorbed due to primary tooth abscess, ectopic eruption was observed in the permanent tooth and that there was a decrease in the arch length as a result of the tooth eruption in the buccal position.¹¹ In this study, the ectopic eruption of premolar teeth was higher than that of the anterior region, and the most common eruption complication in teeth with the ectopic eruption was reduction in the arch length.

The delay in the eruption of teeth with ectopic eruption, impacting, or an early loss of associated primary teeth may reduce the arch length. The reduction in the arch length harms occlusion and tooth alignment and usually increases the need for orthodontic treatment. The use of a space maintainer in the early period may reduce the severity of some problems such as crowding, ectopic eruption, tooth impaction, weak molar association, and arch length reduction.¹⁵

Canine teeth are among the last teeth placed in the dental arch and in the early loss of primary teeth due to caries or trauma,

canine teeth may not be placed in the ideal position. In this case, the direction of the canine tooth changes eruption and it may erupt from the buccal or palatal arch or remain impacted.¹⁶ The ectopic eruption of maxillary canine teeth may lead to the adjacent permanent tooth impaction or resorption. The maxillary lateral root is the area that is mostly affected by the ectopic eruption of canine teeth.¹⁷ Sometimes, even though the lateral teeth erupt normally, in cases such as large tooth size and discrepancy in arch size, they can resorb the mesial parts of the primary canine teeth, usually leading to the early loss of primary canine teeth.² Canine teeth have the longest eruption path in the mouth, and the change in their eruption direction may lead to a delay in eruption. In the present study, the second most common complication was delay in eruption, which was mostly detected in canine teeth.

When the change of complications resulting from ectopic eruption between anterior and posterior teeth was examined, impaction of the tooth and delay in eruption were more commonly observed in the posterior than the anterior. The use of physiological spaces between the primary incisors, the increased axis inclinations of the permanent incisors, monkey diastema, and the increase in intercanine distance play a role in the anterior teeth proper alignment in the arch.¹⁸ The proper alignment of premolar and canine teeth in the arch is achieved using the Leeway space reserves.¹⁹ The lack of one or more of these factors may cause losing necessary space for permanent teeth and ectopic eruption by making a change in the direction of the tooth eruption. Depending on the severity of change in eruption direction, there may be a delay in the eruption of the tooth or it may remain wholly impacted. Early treatment and early onset of treatment, using the natural powers of eruption, can prevent more complex malocclusions.¹⁰ Pedodontists should relate the dental age with each patient's chronological age to diagnose delayed tooth eruption and impacted teeth. The follow-up of

primary, mixed, and permanent teeth is an integral component of comprehensive oral health care for all children.²⁰

The ectopic eruption is considered as a common cause of impacted premolar tooth, however, in some cases, the ectopic tooth's eruption path may spontaneously be in the vertical direction and a normal eruption may occur with the gubernacular cord as the probable cause. Nevertheless, if ectopic second premolars are not treated, they may cause the loss of space in the dental arch due to impacted implantation, and may also lead to the permanent first molar's resorption in very rare cases.³

In cases where the tooth remains wholly impacted, the treatment approach aims to assist the eruption process by stimulating or creating the eruption path. The treatment protocol may include the options of waiting for spontaneous eruption, extraction of the primary tooth from the involved area with spontaneous eruption, surgical exposure, and surgical extrusion.³ In particular, it should be kept in mind that the surgical extrusion procedure is complicated and involves many risk factors such as damage not only to the tooth being treated, but also to the neurovascular nutrition of the jaws alveolar bone and other teeth.³ Early diagnosis is essential to start treatment at the most appropriate time, and thus, to minimize complications.

Teeth with ectopic eruption frequently cause resorption in the adjacent primary tooth, depending on the eruption direction.²¹ In this case, the treatment method is chosen by evaluating the patient's age, the severity of resorption in the primary tooth, and the presence of permanent underlying teeth.²² In cases where the effect is mild, spontaneous recovery can be observed. When spontaneous recovery does not occur, distal tipping treatments, including interproximal wedging and fixed orthodontic treatment can be applied to direct the tooth with ectopic eruption to the eruption path. In cases where the primary tooth cannot remain in the mouth, the only option is tooth extraction and space

maintainer application.¹

The eruption of premolars occurs later than the anterior teeth, and especially, the eruption times of the second premolars may be parallel to the second permanent molar.²³ In the presence of space closure in the dental arch, this situation can be exacerbated by the eruption pressure of second permanent molars, and in the presence of a premolar with ectopic eruption, this tooth may remain impacted. In this study, it was considered that the posterior teeth in the dental arch were affected more in occlusion dynamics than anterior teeth, causing them to be more affected by ectopic eruption complications.

Conclusion

The ectopic eruption was observed to be the most common in premolar teeth, and the most common complication in teeth with the ectopic eruption was the reduction in the arch length. The complications of delay in eruption and impaction, which are frequently observed in premolar teeth due to ectopic eruption, can be resolved by treatment methods that involve creating a new eruption pathway in case of early diagnosis. However, in cases where it is late, complications including severe malocclusion may arise along with the closure of the tooth cavity and reduction of the arch length, due to the tipping of the adjacent tooth into the cavity. Early radiographic diagnosis of ectopic eruption helps reduce the need for potentially more complex orthodontic and surgical treatments along with preventive orthodontic treatments. In this study, the reported prevalence of ectopic erupted anterior and premolar teeth were higher than the other prevalence studies in the literature. Hereditary and genetic factors can be considered in sample selection as a suggestion for future studies.

Conflict of Interests

Authors have no conflict of interests.

Acknowledgments

None.

References

1. Özdemir DS, Onat Altan HN. Ectopic eruption of permanent first molar teeth. *Yeditepe Dental Journal* 2021; 17(1): 69-75.
2. Tirali RE, Erdemci ZY, Çehreli SB. Eruption anomalies. *GÜ Dis Hek Fak Derg* 2011; 28(3): 217-23. [In Turkish].
3. Ismail MQ, Lauridsen E, Andreasen JO, Hermann NV. Ectopic eruption of the second premolar: An analysis of four different treatment approaches. *Eur Arch Paediatr Dent* 2020; 21(1): 119-27.
4. Huber KL, Suri L, Taneja P. Eruption disturbances of the maxillary incisors: A literature review. *J Clin Pediatr Dent* 2008; 32(3): 221-30.
5. Kuvvetli SS, Seymen F, Gencay K. Management of an unerupted dilacerated maxillary central incisor: a case report. *Dent Traumatol* 2007; 23(4): 257-61.
6. Altan H, Akkoc S, Altan A. Radiographic characteristics of mesiodens in a non-syndromic pediatric population in the Black Sea region. *J Investig Clin Dent* 2019; 10(1): e12377.
7. Yaseen SM, Naik S, Uloopi KS. Ectopic eruption - A review and case report. *Contemp Clin Dent* 2011; 2(1): 3-7.
8. Altan A, Çolak S, Akbulut N, Altan H. Radiographic features and treatment strategies of impacted maxillary canines. *Cumhuriyet Dent J* 2020; 23(1): 31-6.
9. Bondemark L, Tsiopa J. Prevalence of ectopic eruption, impaction, retention and agenesis of the permanent second molar. *Angle Orthod* 2007; 77(5): 773-8.
10. Barberia-Leache E, Suarez-Clua MC, Saavedra-Ontiveros D. Ectopic eruption of the maxillary first permanent molar: Characteristics and occurrence in growing children. *Angle Orthod* 2005; 75(4): 610-5.
11. Stephens MB, Wiedemer JP, Kushner GM. Dental problems in primary care. *Am Fam Physician* 2018; 98(11): 654-60.
12. Fux-Noy A. Distal migration and ectopic eruption of the mandibular first premolar: Case report. *J Clin Pediatr Dent* 2020; 44(2): 127-9.
13. Guven Y. Prevalence of ectopic eruption of first permanent molars in a Turkish population. *Eur Oral Res* 2018; 52(1): 1-5.
14. Caliskan S, Tuloglu N, Ozdemir C, Kizilaslan S, Bayrak S. Ectopic eruption of maxillary permanent first molars: Predictive factors for self-corrected and impacted outcome. *Int J Clin Pract* 2021; 75(3): e13880.
15. Law CS. Management of premature primary tooth loss in the child patient. *J Calif Dent Assoc* 2013; 41(8): 612-8.
16. Sajnani AK. Permanent maxillary canines - review of eruption pattern and local etiological factors leading to impaction. *J Investig Clin Dent* 2015; 6(1): 1-7.
17. Saldarriaga JR, Patino MC. Ectopic eruption and severe root resorption. *Am J Orthod Dentofacial Orthop* 2003; 123(3): 259-65.
18. Singh G. Development of occlusion. In: Singh G, editor. *Textbook of orthodontics*. New Delhi, India: Jaypee Brothers Medical Publishers Pvt. Limited; 2008. p. 37-65.
19. Çayönü S, Yüksel BN, Sari Ş. Development of occlusion from the toothless period up to the permanent dentition. *Türkiye Klinikleri J Dental Sci* 2018; 26(1): 110-21.
20. Rai D, Kumar D, Rai D, Kumari D, Chaudhary D. Evaluation of ectopic eruption in teeth's of childrens from 5 to 12 years age group. *IJMBS* 2019; 3(11): 245-51.
21. Kim WS, Kim Y, Cho JH, Oh H, Hwang HS. Unlocking ectopically erupting permanent first molars using light wires. *J Am Dent Assoc* 2020; 151(11): 857-62.
22. Hennessy J, Al-Awadhi EA, Dwyer LO, Leith R. Treatment of ectopic first permanent molar teeth. *Dent Update* 2012; 39(9): 656-1.
23. Karikalan T, Pandey AR. Age estimation based on the pattern of eruption of permanent teeth. *Indian J Forensic Med Pathol* 2017; 10(2): 73-9.