

Rate and comparison of periapical inflammatory lesions using clinical diagnosis and histopathological findings during the 18-year study period

Mehrnaz Karimi-Afshar DDS¹, Molook Torabi DDS, MSc²,
Omid Bidolakhani DDS³, Ali Eskandarizadeh DDS, MSc⁴

Original Article

Abstract

BACKGROUND AND AIM: Inflammatory Periapical lesions are the most common periapical lesions. These lesions are often diagnosed based on clinical and radiological examination, which may be different from the histological finding. The present study was carried out with aim to assess the rate and to compare clinical and radiographic features with histological diagnosis of periapical pathology.

METHODS: This retrospective study was conducted on dental school pathology records in Kerman, Iran, from 1996-2014. Cases with incomplete records and without net histology diagnosis were excluded. Age, gender, site of lesion, clinical diagnosis, and histopathological diagnosis were extracted from the records. The data were analyzed using chi-square test in SPSS software. A P value of 5% was considered as the significance level.

RESULTS: 1854 cases met the inclusion criteria. 129 of the cases were periapical inflammatory lesions. The mean age of individuals was 29.39 ± 15.14 years. Periapical cysts were the most incident lesions in clinical and histopathologic diagnosis. An overall of 98.9% of histopatologic diagnoses were compatible with clinical diagnosis. Inflammatory periapical lesions in maxilla were greater and this difference was significant ($P = 0.001$). Inflammatory periapical lesions were higher among men compared to women, with significant difference ($P = 0.001$).

CONCLUSION: This study showed that periapical cysts were the most incident inflammatory lesions followed by periapical granuloma.

KEYWORDS: Periapical Lesions; Cyst; Granuloma; Incidence; Inflammatory; Odontogenic

Citation: Karimi-Afshar M, Torabi M, Bidolakhani O, Eskandarizadeh A. **Rate and comparison of periapical inflammatory lesions using clinical diagnosis and histopathological findings during the 18-year study period.** J Oral Health Oral Epidemiol 2018; 7(2): 76-9.

Formation of apical inflammatory lesions is a defensive reaction secondary to the presence of microbial infection in the root canal and their toxic products in the apical zone.¹ Periapical lesions are of the most incident pathological conditions within the alveolar bone.²

Periapical granuloma is defined as a mass of chronically or sub-acute inflamed granulation tissue at the apex of a non-vital

tooth. Periapical cyst is formed when the epithelium at the apex of a nonvital tooth is stimulated by inflammation.¹ Histopathological evaluation of periapical lesions is necessary to establish definitive and differential diagnosis.³

Petersson et al. indicated that there is no accurate and correct radiographic method for evaluation of bone changes in periapical area.⁴ Histologic evaluation is the best method for diagnosis and differential diagnosis in periapical lesions.¹ Rate of

1- Resident, Department of Prosthodontics, School of Dentistry, Tehran University of Medical Sciences, Tehran, Iran

2- Associate Professor, Kerman Social Determinants on Oral Health Research Center AND Department of Oral Pathology, School of Dentistry, Kerman University of Medical Sciences, Kerman, Iran

3- Dentist, Private Practice, Mashhad, Iran

4- Associate Professor, Kerman Oral and Dental Diseases Research Center AND Department of Operative Dentistry, School of Dentistry, Kerman University of Medical Sciences, Kerman, Iran

Correspondence to: Molook Torabi DDS, MSc

Email: m.torabi.p@gmail.com

periapical cyst and granuloma is different in different studies. In a study by Koivisto et al., periapical cyst and granuloma were 73.00% of all biopsies.⁵ In a study by Becconsall-Ryan et al. on radiolucent inflammatory jaw lesions, the rate of periapical granuloma and periapical cyst were 59.70% and 29.20% respectively.⁶ Radics et al. showed that 65.20% of surgical periapical lesions were periapical granuloma.⁷ Ali argued that 24.70% of all biopsies in a 6-year period evaluation included radicular cysts.⁸ Berar et al. showed that 63.30% and 18.30% of cases were histologically diagnosed as periapical granuloma and radicular cyst, respectively.³ In a clinicopathologic evaluation of 322 cases by Manor et al., 48.00% of lesions were radicular cyst.⁹ Love and Firth showed that periapical granulomas and cysts were the most common periapical lesions of endodontic origin.¹⁰ Carrillo et al. showed that 65.70% of surgical periapical lesions were periapical granuloma.¹¹ The rate of inflammatory periapical lesions varies in different studies and the final diagnosis of these lesions are based on histopathologic evaluation. Therefore, the present study was performed aiming to evaluate the inflammatory periapical lesions during an 18-year period.

Methods

In this retrospective study, 1872 biopsies were reviewed in pathology department of Kerman dental school in southeast of Iran from 1996-2014. Data including demographic variables (gender, age), site of biopsy, and clinical diagnosis, were collected from pathology archive. Lesions with inadequate material and without net histopathology diagnosis were excluded. Finally, 1854 cases remained for examination. Of 1854 recorded, lesions with periapical granuloma, periapical cysts, and fibrous scar diagnosis and lesions with radiolucent radiographic description were selected. Then slides of these lesions were reviewed by a pathologist according to histopathologic criteria for cyst definition and the data were recorded in a checklist. Then

the obtained data were analyzed by chi-square test in SPSS software (version 21, IBM Corporation, Armonk, NY, USA). A P value of 5% was considered as the significance level. This study was approved by the ethics committee of Kerman University of Medical Sciences with the code k/91/260.

Results

Of 1854 biopsies, 129 cases were periapical inflammatory lesions. The mean age of individuals was 29.39 ± 15.14 years and the age range of patients was between 6-67 years. Clinical diagnosis included 89, 5, 1, 6, 6, and 28 cases of radicular cysts, odontogenic keratocysts (OKC), adenomatoid odontogenic tumor (AOT), residual cyst, osteomyelitis (OM), and periapical granuloma, respectively.

Regarding histopathology examination, 24, 6, and 1 cases were periapical granuloma, residual cyst lesions, and scar tissue, respectively. Regarding residual cysts and OM and fibrous scar, all of clinical diagnoses were compatible with histopathologic diagnosis (Figure 1). In overall, 98.92% of histopathologic diagnoses were compatible with clinical diagnosis.

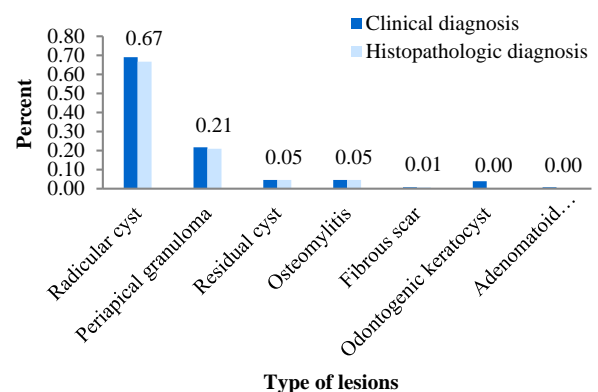


Figure 1. Clinical and histopathological diagnoses according to type of lesions

Inflammatory periapical lesion in maxilla and mandible were 63.50% and 26.50%, respectively and the difference between them was significant ($P = 0.0001$). 56.00% and 44.00% of periapical inflammatory lesions were among men and women, respectively with significant

difference ($P = 0.0001$) (Table 1).

Table 1. Correlation between periapical inflammatory lesions according to gender and location

Variable		n (%)	P
Gender	Men	72 (56.0)	0.0001
	Women	57 (44.0)	
Location	Maxilla	82 (63.5)	0.0001
	Mandible	47 (26.5)	

Discussion

Periapical lesions are of the most incident pathological conditions within the alveolar bone,² and the majority of these lesions include periapical cysts or granulomas.³

The results of the present study showed that the mean age of patients was 29.39 ± 15.14 years, which is similar to the study by Gbadebo et al.¹² In addition, in the present study, radicular cysts were the most incident inflammatory periapical lesions, followed by granuloma periapical. These findings are compatible with some studies like the one conducted by Beconsall-Ryan and Love.¹³ It was revealed that 66.66% of biopsies were radicular cysts, which is in agreement with the study by Selvamani et al.¹⁴ Koseoglu et al.¹⁵ showed that 59.00% of odontogenic cysts were periapical cysts. In the present study, periapical granuloma was the second most incident lesion. This finding is inconsistent with the studies by Koivisto et al.,⁵ Beconsall-Ryan et al.,⁶ and Spatafore et al.,¹⁷ which indicated that dental granuloma were had a higher rate of incidence compared to the periapical cysts. These differences may be due to criteria for cyst diagnosis, as in some cases, epithelial lining of the cyst wall may be destroyed by inflammatory cells. The present study illustrated that lesions were significantly higher among men in comparison with to women. This finding is compatible with the study by Gbadebo et al. indicating a 53.00% rate of periapical inflammatory lesions among men.¹²

It was found in the present study that 4.56% of inflammatory periapical lesions included residual cysts. When periapical cyst

remains after the extraction of the involved tooth, it is called a residual radicular cyst.¹⁸ Periapical cyst and residual cyst have similar histopathologic characteristics.¹⁹

In the present study, 0.07% of lesions were scar tissue. Love and Firth reported a 2% periapical lesions among 100 cases.¹⁰ Scar tissue in the studies by Lin et al.¹⁶ and Beconsall-Ryan et al.⁶ were 2.70% and 0.60%, respectively. In the present study, it was revealed that the majority of the lesions as 63.50% were in maxilla site. This difference was statistically significant. This finding is compatible with similar studies indicating that maxilla was the most common site of inflammatory periapical lesions.^{3,12,16,20,21} Infection of medullary cavity is called OM.¹ It was found in the present study that 4.56% of lesions were OM. This rate is higher than that of the study reported by Beconsall-Ryan et al.⁶ indicating that 0.02% of lesions were OM. This difference may be due to difference of the study method. The higher rate of the samples were clinically diagnosed to be periapical cysts; this was compatible with histopathologic diagnosis. This findings is not compatible with the study by Gbadebo et al.¹² reporting that the majority of the cases were clinically diagnosed to be periapical cyst, however being diagnosed as periapical granuloma in histological examination. Clinical and radiological diagnoses of periapical cyst is based on presence of a well-defined radiolucent lesion associated with a necrotic tooth.^{22,23} Final diagnosis of inflammatory periapical lesions is based on histopathological examinations, in addition, histopathology is more sensitive for diagnosis of periapical cysts and granulomas. However, despite the advantages of using cone-beam computed tomography (CBCT), differentiation of periapical granuloma against cysts are only possible through histological evaluation as CBCT is not sensitive enough.

Conclusion

Based on the findings of the present study, periapical cyst was more incident compared

with other inflammatory periapical lesions. Moreover, lesions in maxilla were more significant than mandible.

Conflict of Interests

Authors have no conflict of interest.

Acknowledgments

The authors hereby would like to thank the research deputy of Kerman University of Medical Sciences for approval and financial support of this project.

References

1. Brad WN, Damm DD, Allen CM, Chi AC. Oral and maxillofacial pathology. Philadelphia, PA: Saunders; 2016. p. 117-23.
2. Diegues LL, Colombo Robazza CR, Costa Hanemann JA, Costa Pereira AA, Silva CO. Correlation between clinical and histopathological diagnoses in periapical inflammatory lesions. *J Investig Clin Dent* 2011; 2(3): 184-6.
3. Berar AM, Bondor CI, Matros L, Campian RS. Radiological, histological and immunohistochemical evaluation of periapical inflammatory lesions. *Rom J Morphol Embryol* 2016; 57(2): 419-25.
4. Petersson A, Axelsson S, Davidson T, Frisk F, Hakeberg M, Kvist T, et al. Radiological diagnosis of periapical bone tissue lesions in endodontics: A systematic review. *Int Endod J* 2012; 45(9): 783-801.
5. Koivisto T, Bowles WR, Rohrer M. Frequency and distribution of radiolucent jaw lesions: A retrospective analysis of 9,723 cases. *J Endod* 2012; 38(6): 729-32.
6. Becconsall-Ryan K, Tong D, Love RM. Radiolucent inflammatory jaw lesions: a twenty-year analysis. *Int Endod J* 2010; 43(10): 859-65.
7. Radics T, Tar I, Bagyi K, Marton I. Prevalence of the various types of periapical lesions and the significance of histologic evaluation. *Fogorv Sz* 2000; 93(4): 108-14. [In Hungarian].
8. Ali MA. Biopsied jaw lesions in Kuwait: A six-year retrospective analysis. *Med Princ Pract* 2011; 20(6): 550-5.
9. Manor E, Kachko L, Puterman MB, Szabo G, Bodner L. Cystic lesions of the jaws - a clinicopathological study of 322 cases and review of the literature. *Int J Med Sci* 2012; 9(1): 20-6.
10. Love RM, Firth N. Histopathological profile of surgically removed persistent periapical radiolucent lesions of endodontic origin. *Int Endod J* 2009; 42(3): 198-202.
11. Carrillo C, Penarrocha M, Bagan JV, Vera F. Relationship between histological diagnosis and evolution of 70 periapical lesions at 12 months, treated by periapical surgery. *J Oral Maxillofac Surg* 2008; 66(8): 1606-9.
12. Gbadebo SO, Akinyamoju AO, Sulaiman AO. Periapical pathology: Comparison of clinical diagnosis and histopathological findings. *J West Afr Coll Surg* 2014; 4(3): 74-88.
13. Becconsall-Ryan K, Love RM. Range and demographics of radiolucent jaw lesions in a New Zealand population. *J Med Imaging Radiat Oncol* 2011; 55(1): 43-51.
14. Selvamani M, Donoghue M, Basandi PS. Analysis of 153 cases of odontogenic cysts in a South Indian sample population: A retrospective study over a decade. *Braz Oral Res* 2012; 26(4): 330-4.
15. Koseoglu BG, Atalay B, Erdem MA. Odontogenic cysts: A clinical study of 90 cases. *J Oral Sci* 2004; 46(4): 253-7.
16. Lin HP, Chen HM, Yu CH, Kuo RC, Kuo YS, Wang YP. Clinicopathological study of 252 jaw bone periapical lesions from a private pathology laboratory. *J Formos Med Assoc* 2010; 109(11): 810-8.
17. Spatafore CM, Griffin JA, Jr., Keyes GG, Wearden S, Skidmore AE. Periapical biopsy report: an analysis of over a 10-year period. *J Endod* 1990; 16(5): 239-41.
18. Moldauer I, Velez I, Kuttler S. Upregulation of basic fibroblast growth factor in human periapical lesions. *J Endod* 2006; 32(5): 408-11.
19. Muglali M, Komerik N, Bulut E, Yarim GF, Celebi N, Sumer M. Cytokine and chemokine levels in radicular and residual cyst fluids. *J Oral Pathol Med* 2008; 37(3): 185-9.
20. Sede MA, Omoregie OF. A clinicopathologic study of periapical lesions obtained during apical endodontic surgery of maxillary anterior teeth. *Annals of Biomedical Sciences* 2011; 10(1): 46-54.
21. Stockdale CR, Chandler NP. The nature of the periapical lesion--a review of 1108 cases. *J Dent* 1988; 16(3): 123-9.
22. Yoshiura K, Weber AL, Runnels S, Scrivani SJ. Cystic lesions of the mandible and maxilla. *Neuroimaging Clin N Am* 2003; 13(3): 485-94.
23. Nair PN. Pathogenesis of apical periodontitis and the causes of endodontic failures. *Crit Rev Oral Biol Med* 2004; 15(6): 348-81.