

## Solitary fibrous tumor of buccal mucosa: A rare entity

Sahar Usman BDS<sup>1</sup>, Zahid Ali BDS, FCPS (OMFS)<sup>2</sup>, Sana Iqbal BDS<sup>3</sup>,  
Ayesha Aslam BDS<sup>3</sup>, Nasir Ud Din MBBS, FCPS (Path.)<sup>4</sup>

### Case Report

#### Abstract

**BACKGROUND AND AIM:** Solitary fibrous tumor (SFT) is a quite uncommon tumor that commonly occurs in the pleura but occasionally involves an oral cavity. We are reporting this rare case in the oral cavity. The diagnosis depends on microscopic and immunohistochemical features. Patients with these tumors can be carefully treated with local excision, but tumors with positive margins necessitate close follow-up over several years due to the possible late local recurrence.

**CASE REPORT:** A 60-year male patient came in the maxillofacial department in Abbasi Shaheed Hospital, Karachi, Pakistan with swelling on lower lip (right side) for the past 5 years which slowly increased in size with no history of pain. The excisional biopsy was performed under local anesthesia. Histopathological examination showed a well-circumscribed spindle cell tumor with alternating hypo and hypercellular areas with prominent collagenous stroma. Immunohistochemistry (IHC) investigation led to the positive expression of Cluster of Differentiation 34 (CD34) and Signal Transducer and Activator of Transcription-6 (STAT-6) in the spindle cells, and negative expression of Anti-Smooth Muscle Antibody (ASMA). Recurrent or postoperative complications were not observed over some time.

**CONCLUSION:** SFT in the buccal mucosa of the cheek is a very sporadic condition. It needs to be identified with proper history and clinical examination.

**KEYWORDS:** Solitary Fibrous Tumors; Neoplasms; Pakistan

**Citation:** Usman S, Ali Z, Iqbal S, Aslam A, Din NU. **Solitary fibrous tumor of buccal mucosa: A rare entity.** *J Oral Health Oral Epidemiol* 2020; 9(2): 104-7.

Solitary fibrous tumors (SFTs) are exceptionally rare entities affecting oral and maxillofacial region. This tumor develops in various other extrapleural locations as well. Its diagnosis is complicated because of its varied morphology and resemblance to other mesenchymal diseases. Currently, there are no known etiological aspects for their origin, and they can include both benign and malignant lesions with metastatic potential.<sup>1</sup> Head and neck are involved in 6% of all SFT cases.<sup>2</sup> It presents as a painless slowly growing, submucosal mass. Histopathological examination along with appropriate immunohistochemistry (IHC) is

required for a definitive diagnosis.<sup>3,4</sup>

The treatment preference is almost whole removal and follow-up is prescribed because of the unreliable conduct of the tumor. Likewise, reports of a potential repeat of SFT consolidate the conduct of this tumor unsure and even powerful in some cases.<sup>5</sup> The utilization of adjuvant treatments, for example, radiotherapy and chemotherapy has been recommended on in instances of inadequate surgical resection of malignant tumors.<sup>4,6</sup> This report as an instance of single stringy tumor in the buccal mucosa, discussed the clinical, pathological, and immunohistochemical highlights utilized for diagnosis.

1- FCPS Resident, Department of Oral and Maxillofacial Surgery, Abbasi Shaheed Hospital, Karachi, Pakistan

2- Professor, Department of Oral and Maxillofacial Surgery, Abbasi Shaheed Hospital, Karachi, Pakistan

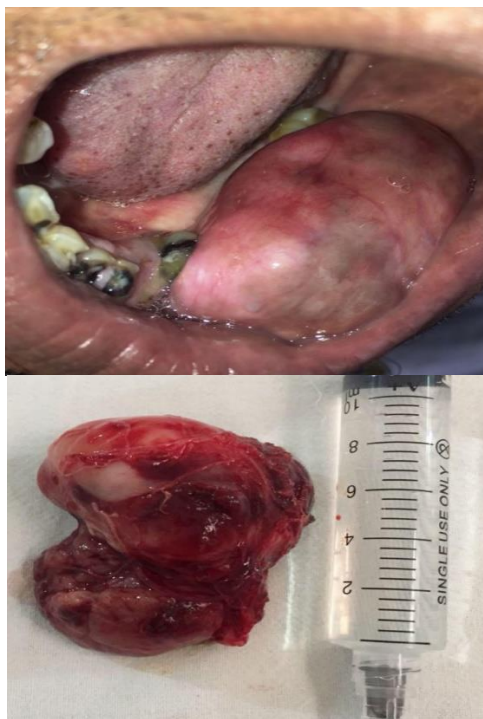3- MCPS Resident, Department of Oral and Maxillofacial Surgery, Abbasi Shaheed Hospital, Karachi Medical and Dental College, Karachi, Pakistan

4- Associate Professor, Department of Pathology and Laboratory Medicine, Aga Khan University Hospital, Karachi, Pakistan

Address for correspondence: Sahar Usman BDS; FCPS Resident, Department of Oral and Maxillofacial Surgery, Abbasi Shaheed Hospital, Karachi, Pakistan; Email: sahar89usman@gmail.com

### Case Report

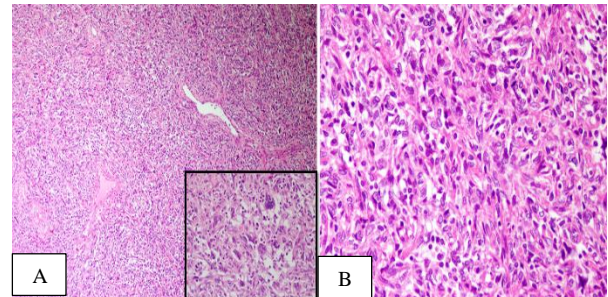
A 60-year-old male patient referred to the Oral and Maxillofacial Surgery Department, Abbasi Shaheed Hospital, Karachi, Pakistan. The patient had a history of swelling on lower lip (right side) for the past five years, which slowly increased in size. There was no history of pain and no known comorbidity. Extra oral physical examination showed a soft, fluctuant, circumscribed, and painless mass. Intraoral examination showed a mucosa covered lump originating from left mandibular canine to posterior area. The lesion involved the entire buccal vestibule and measured  $8 \times 5 \times 4$  cm (Figure 1).



**Figure 1.** A preoperative picture of buccal mucosa and surgical specimen measuring  $8 \times 5 \times 4$  cm

Ultrasound imaging revealed soft tissue lesion on the left side is a heterogeneous lesion with marked vascularity raising suspicious of malignant transformation. Under local anesthesia, the tumor was excised. Grossly, the tumor was oval-shaped with a smooth brown surface (Figure 1). Histopathological analysis showed a neoplastic lesion composed of fascicles of spindle-shaped cells with

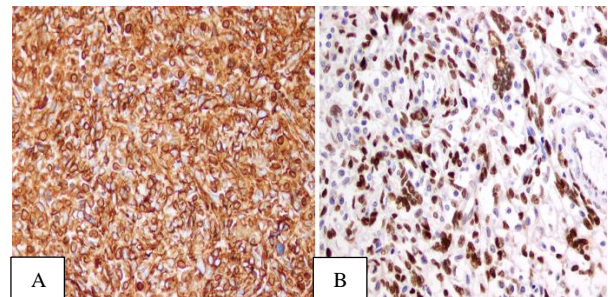
prominent collagenous stroma and spindle-shaped cells exhibited mild pleomorphism. No mitosis and necrosis were observed. Few thin-walled small vessels with stromal multinucleated giant cells were also present (Figure 2, A and B).



**Figure 2.** Histological features of a solitary fibrous tumor (SFT)

Tumor cells are present among dilated vessels. Inset shows multinucleated cells lining small spaces (A), Tumor cells exhibit mild atypia (B)

The immunohistochemical studies showed positivity for Cluster of Differentiation 34 (CD34) and Signal Transducer and Activator of Transcription-6 (STAT-6) (Figure 3, A and B) and negative staining for S100 and Anti-Smooth Muscle Antibody (ASMA). The proliferation index (Ki 67) was low.

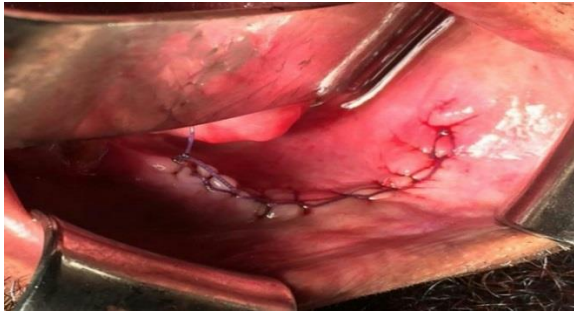


**Figure 3.** Immunohistochemical (IHC) features of a solitary fibrous tumor (SFT)

Positive Cluster of Differentiation 34 (CD34) IHC stain (A) and Positive Signal Transducer and Activator of Transcription-6 (STAT-6) IHC stain (B)

The final diagnosis of SFT was made based on histopathological and immunohistochemical features.

The patient did well postoperatively and is currently under regular follow-up with no post-surgery signs and symptoms of recurrence (Figure 4).



**Figure 4.** Operative incision closed with sutures

### Discussion

A SFT is a tumor of fibroblastic origin and is recognized to occur mainly in the pleura, but it also occurs in extrapleural sites such as peritoneum, pericardium, and mediastinum. It was described to have arisen in epithelial organs, such as thyroid, paranasal sinus, orbit, lacrimal gland, and skin.<sup>7,8</sup> In a review article by Cox et al.,<sup>6</sup> out of the 153 cases of SFT reported in the head and neck region, 26.1% developed in the buccal mucosa, 9.2% in the nasal cavity, 7.8% in the pharynx, 7.2% in a tongue, and 6.5% in the orbit. The reappearance rate of SFT occurring in the pleura is reported to be approximately 30.0%. In contrast, the reappearance of a SFT in an oral lesion is rare. Expanding the scope to include head and neck lesions increases the recurrence rate to 40.0%.<sup>9</sup>

SFT happening in the oral or maxillofacial locale is amazingly uncommon, and the conduct of SFT at this area is not plainly comprehended. SFT is considered as a middle of the road of the fibroblastic tumor in the World Health Organization (WHO) grouping of tumors of soft tissue and bone.<sup>10</sup> SFTs do not show unmistakable highlights on computerized tomography (CT) scan or magnetic resonance imaging (MRI).

The diagnosis depends on the findings acquired in a histological examination. Neurofibroma, schwannoma, leiomyoma, and hemangiopericytoma are the lesions that should be differentiated from SFT. For differential diagnosis, Hematoxylin and Eosin (H&E) staining and immunohistochemical staining are used.

Histologically, a 'patternless pattern' of

spindle cells in alternating hypo and hypercellular areas are characteristic to SFT. The hypercellular areas are composed of plump spindle cells with intervening fine reticular collagen. In hypocellular areas, thick collagen fibers and myxoid stroma are noted. Hemangiopericytoma-like vessels are usually seen as a pattern.<sup>11</sup> Immunohistochemically, SFT shows positivity for CD34 and STAT6. Our case showed diffuse expression for both CD34 and STAT-6 cells and negative response to ASMA. CD34 can be positive in other mesenchymal tumors as well, such as the Dermatofibrosarcoma Protuberans (DFSP), spindle cell lipoma, and hemangiopericytoma. As a result, it is difficult to use CD34 as a definite marker of a SFT. Recently, STAT 6 has been described to be a sensitive and specific marker for SFT.<sup>12</sup>

Generally, SFT grows painlessly and slowly over time. Due to this nature, it grows to a significant size before it is detected.<sup>13,14</sup> The main complains are dysarthria or masticatory disorder when SFT involves oral cavity.<sup>15</sup>

A SFT is treated by complete surgical excision. Most SFTs are benign, with generally good prognosis. Malignancy in SFT has been evident. If a malignant SFT is reported on biopsy, more aggressive treatment should be considered, such as wide margin excision. The case reported herein was arbitrated as a benign tumor, and recurrence was not observed until the time of completing the study, but as it may recur, long-term follow-up is compulsory.<sup>16</sup>

### Conclusion

The SFT in the buccal mucosa of the cheek is a very sporadic condition. It needs to be identified with proper history and clinical examination.

### Conflict of Interests

Authors have no conflict of interest.

### Acknowledgments

The authors would like to appreciate the efforts of Dr. Mehwash Kashif, Head of Department of Oral Pathology, for her critical review, correction, and guidance.

## References

1. Bauer JL, Miklos AZ, Thompson LD. Parotid gland solitary fibrous tumor: A case report and clinicopathologic review of 22 cases from the literature. *Head Neck Pathol* 2012; 6(1): 21-31.
2. Gold JS, Antonescu CR, Hajdu C, Ferrone CR, Hussain M, Lewis JJ, et al. Clinicopathologic correlates of solitary fibrous tumors. *Cancer* 2002; 94(4): 1057-68.
3. Carlos R, de Andrade BA, Canedo NH, Abrahao AC, Agostini M, de Almeida OP, et al. Clinicopathologic and immunohistochemical features of five new cases of solitary fibrous tumor of the oral cavity. *Oral Surg Oral Med Oral Pathol Oral Radiol* 2016; 121(4): 390-5.
4. Yang XJ, Zheng JW, Ye WM, Wang YA, Zhu HG, Wang LZ, et al. Malignant solitary fibrous tumors of the head and neck: A clinicopathological study of nine consecutive patients. *Oral Oncol* 2009; 45(8): 678-82.
5. Sousa AA, Souto GR, Sousa IA, Mesquita RA, Gomez RS, Jham BC. Solitary fibrous tumor of the parotid gland: Case report. *J Clin Exp Dent* 2013; 5(4): e208-e211.
6. Cox DP, Daniels T, Jordan RC. Solitary fibrous tumor of the head and neck. *Oral Surg Oral Med Oral Pathol Oral Radiol Endod* 2010; 110(1): 79-84.
7. Mupas-Uy J, Kitaguchi Y, Takahashi Y, Takahashi E, Kakizaki H. Solitary fibrous tumor in the lacrimal gland fossa: A case report. *Case Rep Ophthalmol* 2016; 7(2): 398-403.
8. Morales-Cadena M, Zubiaur FM, Alvarez R, Madrigal J, Zarate-Osorno A. Solitary fibrous tumor of the nasal cavity and paranasal sinuses. *Otolaryngol Head Neck Surg* 2006; 135(6): 980-2.
9. Smith SC, Gooding WE, Elkins M, Patel RM, Harms PW, McDaniel AS, et al. Solitary fibrous tumors of the head and neck: A multi-institutional clinicopathologic study. *Am J Surg Pathol* 2017; 41(12): 1642-56.
10. Fletcher CD. The evolving classification of soft tissue tumours: An update based on the new WHO classification. *Histopathology* 2006; 48(1): 3-12.
11. Chang YL, Lee YC, Wu CT. Thoracic solitary fibrous tumor: Clinical and pathological diversity. *Lung Cancer* 1999; 23(1): 53-60.
12. Doyle LA, Vivero M, Fletcher CD, Mertens F, Hornick JL. Nuclear expression of STAT6 distinguishes solitary fibrous tumor from histologic mimics. *Mod Pathol* 2014; 27(3): 390-5.
13. Smith MH, Islam NM, Bhattacharyya I, Cohen DM, Fitzpatrick SG. STAT6 reliably distinguishes solitary fibrous tumors from myofibromas. *Head Neck Pathol* 2018; 12(1): 110-7.
14. Raghani N, Raghani MJ, Rao S, Rao S. Hemangiopericytoma/solitary fibrous tumor of the buccal mucosa. *Ann Maxillofac Surg* 2018; 8(1): 151-3.
15. Migita M, Yoshino M, Kobayashi D, Shiomi S, Enatsu K, Shigematsu S, et al. A large solitary fibrous tumor of the tongue. *J Oral Maxillofac Surg* 2012; 70(4): 871-4.
16. Anders JO, Aurich M, Lang T, Wagner A. Solitary fibrous tumor in the thigh: Review of the literature. *J Cancer Res Clin Oncol* 2006; 132(2): 69-75.