

## Effect of extraction of permanent first molars on the development and eruption of third molars

Raziyeh Shojaeipoor DDS<sup>1</sup>, Azadeh Horri DDS<sup>1</sup>, Hamid Sharifi PhD<sup>2</sup>,  
Sudeh Mohseni DDS<sup>3</sup>

### Original Article

#### Abstract

**BACKGROUND AND AIM:** It is required in many young patients that permanent first molars (PFMs) be extracted due to poor prognosis. This study investigates whether the extraction of such teeth is effective on the development of third molars and even their crown and root morphologies.

**METHODS:** A total of 7000 panoramic radiographs were evaluated and 128 radiographs showing a history of extraction of PFMs on one side in one jaw or both jaws, with the third molars present in the same jaw on both sides, were selected. The third molar on the first molar extraction side was considered the case and the third molar on the other side was considered the control. The case and control third molars were compared in relation to their development, impaction, number of roots, mesiodistal width, root length, and curvature of apex.  $P < 0.05$  was considered significant. Data were analyzed using SPSS software.

**RESULTS:** On 128 panoramic radiographs evaluated, Olze and Demirjian factors showed that in most cases the crown development of the third molars on the control side lagged behind that on the case side. On the control side, the third molars had two roots in 66.9% and on the case side had two roots in 75.8%.

**CONCLUSION:** Extraction of PFMs at a proper time might accelerate the development of the third molars on the same side and affect the morphologies of the crown and root(s) of third molars.

**KEYWORDS:** Extraction; Permanent; Molar

**Citation:** Shojaeipoor R, Horri A, Sharifi H, Mohseni S. **Effect of extraction of permanent first molars on the development and eruption of third molars.** J Oral Health Oral Epidemiol 2018; 7(3): 126-31.

Treatment of a permanent first molar (PFM) with a poor long-term prognosis is challenging in terms of the dentist's knowledge and expertise.<sup>1,2</sup> Caries is the most common reason for extraction of such teeth,<sup>3-5</sup> and other reasons include chronological enamel defects,<sup>6,7</sup> unrestorable nature of the tooth, and lack of patient cooperation.<sup>8</sup> One of the conditions for the extraction of PFMs is the presence of the third molar tooth bud on the radiograph on the extraction side.<sup>9</sup> Third molars are the last teeth in the permanent

dentition to erupt and their time of development is very variable. They are the most common teeth to be missing. The impaction of these teeth is very prevalent and is mainly bilateral, and variations in the anatomy of their crowns and roots are not uncommon.<sup>10</sup> Research has shown that extraction of PFMs accelerates the development of third molars.<sup>11</sup> The morphology of the third molar root can be evaluated on radiographs. The anatomy of the root canal and morphology of third molars are very variable, the presence of two

1- Assistant Professor, Oral and Dental Diseases Research Center AND Kerman Social Determinants of Oral Health Research Center AND Department of Pediatric Dentistry, School of Dentistry, Kerman University of Medical Sciences, Kerman, Iran

2- Associate Professor, HIV/STI Surveillance Research Center, and WHO Collaborating Center for HIV Surveillance, Institute for Futures Studies in Health, Kerman University of Medical Sciences, Kerman, Iran

3- Assistant Professor, Department of Oral and Maxillofacial Radiology, School of Dentistry, Kerman University of Medical Sciences, Kerman, Iran

Correspondence to: Azadeh Horri DDS  
Email: [azadehorri@gmail.com](mailto:azadehorri@gmail.com)

roots in mandibular third molars is considered a normal anatomy.<sup>12-14</sup> In 80.5% of cases, the root morphologies of the same teeth are similar on both sides of the mandible.<sup>15</sup> The eruption times of teeth in the same class are very similar.<sup>16</sup> Halicioglu et al. evaluated 2925 panoramic radiographs in a retrospective study, belonging to subjects with 13-20 years of age, in order to diagnose cases with at least one PFM having been extracted. A total of 294 eligible radiographs were selected for the evaluation of the developmental stage of third molars. The results showed that the eruption of the third molar on the extraction side accelerated significantly in both the upper and lower jaws.<sup>1</sup> Yavuz et al. evaluated the panoramic radiographs and dental casts of 165 adolescents who had lost the PFM on one side, in order to determine the developmental stage of third molars, reporting that early loss of PFM on one side accelerated the development of the third molar compared to the contralateral side.<sup>2</sup> So far, researches have shown that extraction of PFM can accelerate the eruption of the third molar on the same side. However, the present study evaluates the effect of early loss of PFMs on the development and eruption of third molars. In this context, apart from affecting the eruption time of the third molar on the same side, morphologies of the crown and root of the third molar might be affected.

### Methods

The protocol of the present retrospective descriptive-analytical study was approved by the Ethics Committee of Kerman University of Medical Sciences, Kerman, Iran, (under the code IR.kmu.rec.1394.337). A total of 7000 panoramic radiographs available in an oral and maxillofacial radiology center were evaluated by two pedodontists to select radiographs based on inclusion and exclusion criteria by visualizing the radiographs on a computer monitor. All the radiographs had been taken with a PaX-i x-ray machine (Vatech, South Korea) using the following

exposure conditions: current = 10 mA, time = 10 s, voltage = 68-71 kVp, based on age, gender and frame size of the patients. The radiographs were visualized on a Ben XL2430T LED monitor with a resolution of 1920×1080 pixels in the milieu of Easy Dental software program. A total of 128 eligible radiographs were selected for the evaluation of third molars based on the following criteria:

Radiographs with no distortion and anomalies

Extraction of one PFM in the jaw in which two third molars were present

The following cases were excluded from the study:

No agreement between the two observers to reach a diagnosis

Low-quality radiographs

Presence of a definite lesion on the radiograph

On the radiographs, the third molar on the PFM extraction side was considered to be the case side and the contralateral side in the same jaw was considered as the control side, which was compared for the following criteria:

1. Comparison of the eruption status based on Olze classification<sup>17</sup>

Stage A: The occlusal plane of the tooth is covered with the alveolar bone.

Stage B: Alveolar emergence; complete resorption of the alveolar bone on the occlusal plane

Stage C: Gingival emergence; penetration of at least one tooth cusp into the gingiva

Stage D: Complete observation of the tooth in the occlusal plane

2. Comparison of the developmental stage based on Demirjian method<sup>17</sup>

Stage A: The cusp tips are calcified but are not connected to each other.

Stage B: Calcified cusps are connected to each other and the occlusal surface morphology is clearly visible.

Stage C: Half of the crown has been formed and the pulp chamber is visible.

Stage D: The tooth crown formed up to the pulp chamber is visible.

Stage E: The formation of the root and inter-radicular bifurcation has begun and the root length is less than the crown length.

Stage F: The length of the root is at least the same as the length of the crown and the root end is funnel-shaped.

Stage G: The root walls are parallel but the apex is open.

Stage H: The apex has been closed completely and the periodontal ligament has surrounded the root with a homogeneous width.

3. Comparison of the position (impaction):<sup>18</sup> the presence of hard tissue on the occlusal surface partially or completely was considered impaction and the absence of hard tissue on the occlusal surface was considered absence of impaction.

4. Comparison of the number of roots<sup>18</sup>

5. Comparison of the morphology:<sup>18</sup> the largest mesiodistal widths of the two teeth were measured and compared with the use of SCANORA 4.3.1 software program.

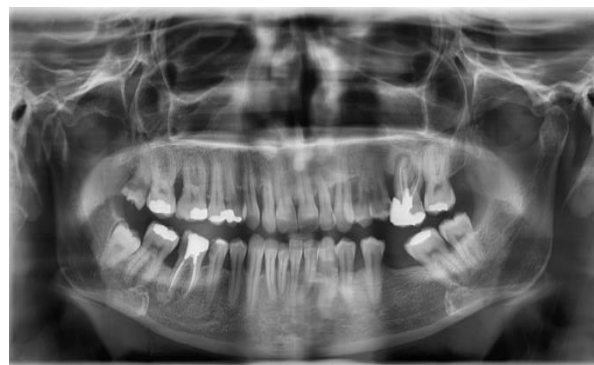Data were analyzed with McNemar's and Wilcoxon's tests in SPSS software (version 21, IBM Corporation, Armonk, NY).  $P < 0.05$  was considered significant.

## Results

Of 128 eligible radiographs, 78.0% and 21.9% exhibited extraction of PFMs in the mandible and maxilla, respectively. Descriptive analyses were used for qualitative data and estimation of 95% confidence interval (CI).

In the present study, Olze factor was used to compare the development of tooth crowns between the case and control sides. In 75% of cases, the two sides were in stage D of development, and in 25% of cases the developmental stages were different on the two sides; in the majority of cases (30 of 32 cases) the development of the crown of the third molar on the control side lagged behind that on the case side, which was statistically significant ( $P = 0.001$ ) (Figure 1).

Table 1 presents the frequencies of the developmental stages of third molar crowns on the case and control sides in terms of Olze factor.



**Figure 1.** The case and control lower third molars were compared in relation to their development, impaction, number of roots, and the mesiodistal width of crown

Based on Demirjian factor, the differences in the development of third molars were compared between the case and control sides. In 85.2% of cases the developmental stage of the third molars was H on both sides, and in 8.5% of cases (11 of 128 cases), mostly the developmental stage of the third molar on the case side was higher (more developed) than that on the control side, which was statistically significant ( $P = 0.002$ ).

**Table 1.** The frequencies of the developmental stages of third molar crowns on the case and control sides in terms of Olze factor

Control Case	A	B	C	D	Total
A	3	0	0	0	3
B	1	0	0	0	1
C	0	0	1	2	3
D	0	4	23	94	121
Total	4	4	24	96	128

The P-value is significant at the 0.001 level

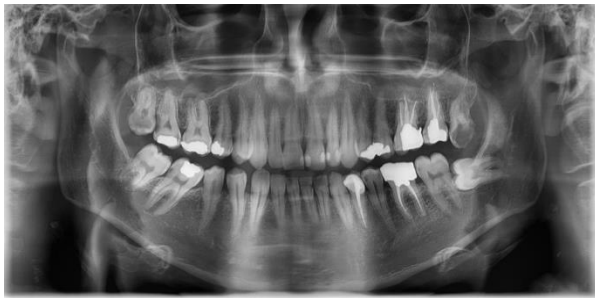Table 2 presents the frequencies of the developmental stages of third molars on the case and control sides in terms of Demirjian factor.

In the present study, of 128 radiographs, in 123 radiographs the impaction status of third molars was the same on both sides, and in the remaining 5 cases it was different; in 80% of these cases (4 out of 5) the third molar on the case side had erupted but it was impacted on the control side. This difference was statistically significant ( $P = 0.001$ ) (Figure 2).

**Table 2.** The frequencies of developmental stages of third molars on the two sides in terms of Demirjian factor

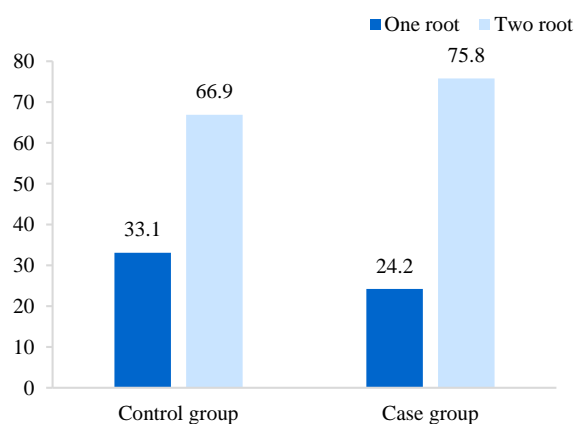
Case	Control	C	D	E	F	G	H	Total
C	2	0	0	0	0	0	0	2
D	0	2	0	0	0	0	0	2
E	0	0	0	1	0	0	0	1
F	0	0	0	0	0	0	0	0
G	0	0	0	0	1	3	0	4
H	0	0	0	0	4	6	109	119
Total	2	2	2	1	5	9	109	128

The P-value is significant at the 0.002 level



**Figure 2.** The case and control lower third molars were compared in relation to their impaction

In 124 radiographs, the formation of the root(s) of third molars was comparable on both sides. On the control side, the third molars were two-rooted and single-rooted in 66.9% and 33.1% of cases, respectively; however, on the case side, the third molars were two-rooted and single-rooted in 75.8% and 24.2% of cases (Figure 3). This difference was significant statistically ( $P = 0.013$ ).

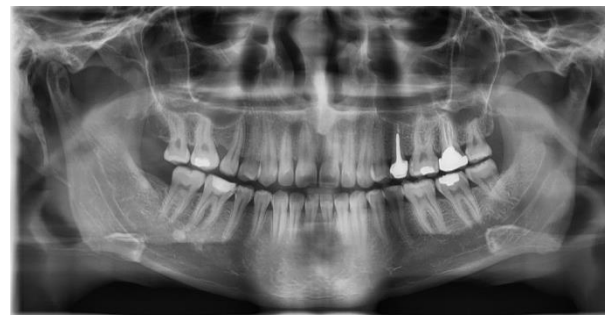

**Figure 3.** The frequencies of the number of roots in third molars on the case and control sides

Of 128 radiographs evaluated, 15 radiographs (11.7%, 95% CI: 6.7-18.6) exhibited differences in the third molar tooth morphology between the two sides; in 14 out

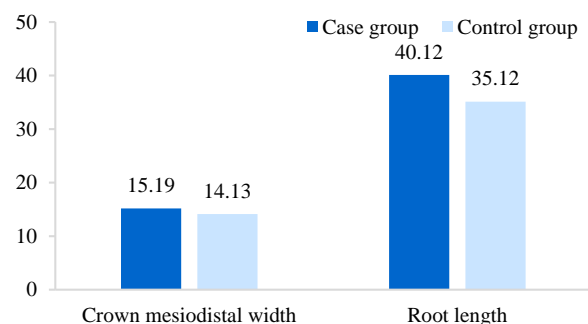
of 15 such cases, the mesiodistal width of the tooth on the case side was larger than the control side.

In 128 radiographs evaluated, 5 cases were excluded from the study due to the absence of root formation; in 40 of the 123 remaining cases (32.5%, 95% CI: 24.4-41.6), there were differences in the root length between the case and control cases, with longer roots in 95 cases (87.5%) and longer roots in 5 cases on the control side (Figure 4).



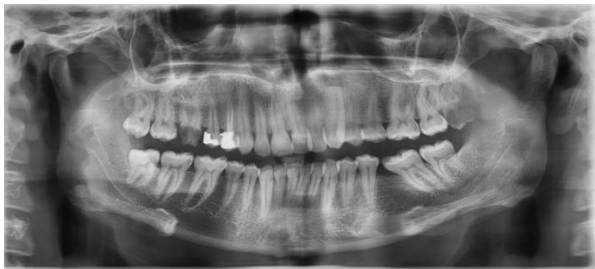**Figure 4.** The case and control upper third molars were compared in relation to their root length

Figure 5 presents differences in the mesiodistal width of the crowns and root lengths.



**Figure 5.** Differences (percent) in root lengths and the mesiodistal widths of the crowns between the case and control sides

Of 128 radiographs evaluated, 6 radiographs were excluded from the study due to the absence of root formation or lack of agreement between the two observers on apex curvature. Of 122 remaining cases (29.5%, 95% CI: 21.6-38.4), 36 cases exhibited differences between the case and control sides, with apex curvature in 33 cases on the control side (Figure 6).



**Figure 6.** The case and control lower third molars were compared in relation to their impaction, the root length, and the curvature of the apex

### Discussion

There is limited research available on the effect of extraction of PFMs on acceleration of eruption of third molars on the extraction side compared to the other side of the same jaw. The results showed that the third molars on the case side were more developed than those on the control side. Studies by Halicioglu et al.<sup>1</sup> and Yavuz et al.<sup>2</sup> also confirmed this finding.

In the present study, in 5 radiographs, on the side where the PFM had been extracted the third molar had erupted, and on the other side of the same jaw the third molar was impacted. However, it is possible to follow up the idea that although the eruption times of teeth in the same class are very close to each other,<sup>16</sup> the development and eruption of the third molar, compared to the other side of the jaw, is affected by the extraction of PFMs. Evaluation of radiographs in the present study showed that extraction of PFMs can affect the third molars in relation to their having separate roots irrespective of the separate or fused roots of the third molar on the contralateral side; this is despite the fact that in 80.5% of individuals the morphology

of the roots of the same teeth on the two sides of the same jaw is similar.<sup>15</sup> In the present study, the third molar teeth on the PFM extraction side had larger crowns and longer roots with no curvature in the apex compared to the third molar on the contralateral side of the jaw. No similar study was found; therefore, it is suggested that further studies be carried out, especially prospective studies, on the subject in order to determine the proper time for the extraction of PFMs in terms of its effect on the development and morphology of the crown and root(s) of third molar, so that such teeth can play a better role in the occlusion of patients who have lost their PFMs.

Some of the limitations of the present study consisted of its retrospective nature and the fact that the time of extraction of PFM was not decided by the researchers. Therefore, this study points to a possible hypothesis that might be substantiated by prospective studies, indicating that if the extraction time of a PFM with poor prognosis is ideal, it not only does provide adequate space for the eruption of the third molar, but also this space helps express the genes of teeth with long, straight and separate roots, even affecting the morphology of the crown in the form of a larger mesiodistal width. In the present retrospective study, it was not possible to evaluate age and gender. In addition, as shown on some panoramic radiographs, the PFM had not been extracted at an ideal time; therefore, the edentulous space had not been closed completely or an abnormal deviation in the longitudinal axis of the teeth adjacent to the edentulous space was evident; however, the development of the third molar had been affected.

### Conclusion

If PFMs with poor prognosis are extracted at a proper time, adequate space will be provided for the eruption of third molars, and it is probable that a third molar tooth with a larger crown, longer root(s) with no curvature and even separate roots, compared

to the third molar tooth on the contralateral side, will prove efficacious in the long-term function of the oral cavity.

### Conflict of Interests

Authors have no conflict of interest.

### Acknowledgments

The authors of the present study sincerely appreciate the authorities of research committee of Kerman University of Medical Sciences for their financial support of the project.

### References

1. Halicioglu K, Toptas O, Akkas I, Celikoglu M. Permanent first molar extraction in adolescents and young adults and its effect on the development of third molar. *Clin Oral Investig* 2014; 18(5): 1489-94.
2. Yavuz I, Baydas B, Ikbali A, Dagsuyu IM, Ceylan I. Effects of early loss of permanent first molars on the development of third molars. *Am J Orthod Dentofacial Orthop* 2006; 130(5): 634-8.
3. Teo TK, Ashley PF, Derrick D. Lower first permanent molars: Developing better predictors of spontaneous space closure. *Eur J Orthod* 2016; 38(1): 90-5.
4. Cobourne MT, Williams A, Harrison M. National clinical guidelines for the extraction of first permanent molars in children. *Br Dent J* 2014; 217(11): 643-8.
5. Alesia K, Khalil HS. Reasons for and patterns relating to the extraction of permanent teeth in a subset of the Saudi population. *Clin Cosmet Investig Dent* 2013; 5: 51-6.
6. Mohammadi Z, Jafarzadeh H, Shalavi S, Bandi S, Patil S. Root and root canal morphology of human third molar teeth. *J Contemp Dent Pract* 2015; 16(4): 310-3.
7. Caglaroglu M, Kilic N, Erdem A. Effects of early unilateral first molar extraction on skeletal asymmetry. *Am J Orthod Dentofacial Orthop* 2008; 134(2): 270-5.
8. Albadri S, Zaitoun H, McDonnell ST, Davidson LE. Extraction of first permanent molar teeth: Results from three dental hospitals. *Br Dent J* 2007; 203(7): E14-E19.
9. Byahatti S, Ingafou MS. Prevalence of eruption status of third molars in Libyan students. *Dent Res J (Isfahan)* 2012; 9(2): 152-7.
10. Innes N, Borrie F, Bearn D, Evans D, Rauchhaus P, McSwiggan S, et al. Should I eXtract Every Six dental trial (SIXES): study protocol for a randomized controlled trial. *Trials* 2013; 14: 59.
11. Nakamori K, Tomihara K, Noguchi M. Clinical significance of computed tomography assessment for third molar surgery. *World J Radiol* 2014; 6(7): 417-23.
12. Kuzekanani M, Haghani J, Nosrati H. Root and canal morphology of mandibular third molars in an Iranian population. *J Dent Res Dent Clin Dent Prospects* 2012; 6(3): 85-8.
13. Santosh P. Impacted mandibular third molars: Review of literature and a proposal of a combined clinical and radiological classification. *Ann Med Health Sci Res* 2015; 5(4): 229-34.
14. Monirifard M, Yaraghi N, Vali A, Vali A, Vali A. Radiographic assessment of third molars development and its relation to dental and chronological age in an Iranian population. *Dent Res J (Isfahan)* 2015; 12(1): 64-70.
15. Park JB, Kim N, Park S, Ko Y. Evaluation of number of roots and root anatomy of permanent mandibular third molars in a Korean population, using cone-beam computed tomography. *Eur J Dent* 2013; 7(3): 296-301.
16. Kjevar I. Mechanism of human tooth eruption: Review article including a new theory for future studies on the eruption process. *Scientifica* 2014; 2014: 341905.
17. Schmeling A, Grundmann C, Fuhrmann A, Kaatsch HJ, Knell B, Ramsthaler F, et al. Criteria for age estimation in living individuals. *Int J Legal Med* 2008; 122(6): 457-60.
18. Roy I, Baliga SD, Louis A, Rao S. Importance of clinical and radiological parameters in assessment of surgical difficulty in removal of impacted mandibular 3rd molars: A new index. *J Maxillofac Oral Surg* 2015; 14(3): 745-9.