

Clinical evaluation of the effect of gingival thickness on increasing the width of keratinized and attached gingiva with and without preserving periosteum in an animal study

Saeedeh Ebrahimi DDS, MSc¹, Jalil Abshenas DVM, DVSC²,
 Mohammad Mehdi Molaei DVM, DVSC³, Mohammad Mohammadi DDS, MSc⁴,
 Nastaran Karimi DDS, MSc⁵

Original Article

Abstract

BACKGROUND AND AIM: The present study was performed in order to assess the effect of gingival thickness on amount of gingival augmentation with and without preserving periosteum.

METHODS: The study was conducted on 8 ecotype dogs aged 1-5 years. At the beginning, clinical probing depth and keratinized and attached gingiva width were measured. Totally, 64 sites were operated in this study. Periosteal fenestration and denuded beds were randomly created on opposite sides of upper and lower jaws (4 sites each side). The thickness of gingiva was measured in mucogingival junction after preparation of the beds. The clinical parameters were evaluated 2 months after the surgery. The data were analyzed by Mann-Whitney U, Wilcoxon, and Pearson correlation tests.

RESULTS: The results showed the average increased width of keratinized and attached gingiva was 1.8 mm and 2 mm in periosteal fenestration sites and 1.9 mm and 2.3 mm in denudation sites, respectively at 2 months post-surgery. The difference between the width of keratinized gingiva and attached gingiva before and 2 months after operation was significant in both groups ($P < 0.001$). However, no significant difference was shown between the two groups in terms of attached and keratinized gingival width ($P = 0.100$ and $P = 0.720$, respectively). There was no correlation between the thickness of gingiva and the amount of increased width of keratinized and attached gingiva.

CONCLUSION: A gingival thickness of 0.8 to 2 mm does not affect the increment of the attached and keratinized gingival width with and without preserving periosteum.

KEYWORDS: Gingiva; Denudation; Surgery

Citation: Ebrahimi S, Abshenas J, Molaei MM, Mohammadi M, Karimi N. **Clinical evaluation of the effect of gingival thickness on increasing the width of keratinized and attached gingiva with and without preserving periosteum in an animal study.** *J Oral Health Oral Epidemiol* 2017; 6(3): 145-50.

In the field of periodontology, a minimum width of attached gingiva is necessary for maintaining health of periodontium, particularly in orthodontic or prosthetic treatments to increase the removal of plaque around the gingival margin, improve esthetic, and reduce

inflammation around the restored teeth.¹ In people with poor oral hygiene, sufficient width of keratinized gingiva and vestibular depth help keep oral hygiene.² Sufficient attached gingiva is essential around the abutment teeth of the fixed or removable partial prosthesis.³ Teeth with restorations involving subgingival

1- Assistant Professor, Department of Oral and Maxillofacial Radiology, School of Dentistry, Birjand University of Medical Sciences, Birjand, Iran

2- Associate Professor, Department of Clinical Sciences, School of Veterinary Medicine, Shahid Bahonar University of Kerman, Kerman, Iran

3- Professor, Department of Clinical Sciences, School of Veterinary Medicine, Shahid Bahonar University of Kerman, Kerman, Iran

4- Assistant Professor, Oral and Dental Diseases Research Center AND Kerman Social Determinants on Oral Health Research Center AND Department of Periodontics, School of Dentistry, Kerman University of Medical Sciences, Kerman, Iran

5- Private Practice, Bandar Abbas, Iran

Correspondence to: Mohammad Mohammadi DDS, MSc

Email: m_mohammadi@kmu.ac.ir

margins and narrow attached gingiva are shown to be more inflamed than similar teeth with wide attached gingiva.⁴

Over the years, periodontists have introduced numerous techniques for gingival augmentation around the teeth. These techniques include, denudation, periosteal retention and fenestration, free gingival and connective tissue grafts and also alloderm and tissue engineering techniques.⁵⁻¹³

Various studies have shown that gingival thickness is effective for successful root coverage and regenerative treatments.^{14,15} Because of the complications of free soft tissue graft techniques¹⁶ and the high costs of tissue engineering techniques for preparing gingival grafts in terms of time and money,^{17,18} it is preferred to find a simple technique that does not require the graft donor site and with predictable results. Periosteal fenestration technique and denudation technique are simple techniques introduced to increase the width of keratinized and attached gingiva, but with unpredictable results.^{8,19} In some cases, other techniques are used today such as frenectomy. For example, after frenectomy, we should decide to use a soft tissue graft to increase the attached gingiva or not. Therefore, if the thickness of gingiva is an effective factor on gingival augmentation in periosteal fenestration and denudation techniques, we can make a decision about the kind of technique (a bed without graft or with graft). However, because, the factors affecting the clinical results of these two techniques have not yet been evaluated, this study was conducted to determine the effect of gingival thickness on increasing the width of attached and keratinized gingiva.

Methods

The present research was an animal study. Considering that the dogs' periodontium is clinically and histologically similar to that of humans, this study was conducted on dogs.²⁰ The study population consisted of 8 ecotype dogs (4 females and 4 males) aged 1 to 5 years

that received rabies vaccine and antiparasitic treatments one month prior to the beginning of the study in order to meet the inclusion criteria. The appropriate ethical license (No. 698) was obtained from the Ethics Committee of Kerman University of Medical Sciences, Kerman, Iran.

The keratinized gingival width (the distance between the gingival margin and the mucogingival junction) at the mid-buccal area and also the mid-buccal probing depth of the examined tooth (mandibular and maxillary second and fourth premolars) were measured by a clinician who was blind to the study, using a Williams probe (Jooya, Tehran, Iran) with 1 mm accuracy. The attached gingival width at the mid-buccal area was measured by subtracting the probing depth from the keratinized gingiva width of the examined teeth. These measurements were performed on the dogs before the surgery and 2 months after operation.

The attached gingival thickness at the mid-facial area was measured at the mucogingival junction using a Williams probe with a rubber stop. The gingival thickness was then measured to the tenth of a millimeter using a caliper. The gingival thickness was measured during surgery after making an incision in the mucogingival junction and pushing the apical tissue aside for preparing the bed (Figure 1).

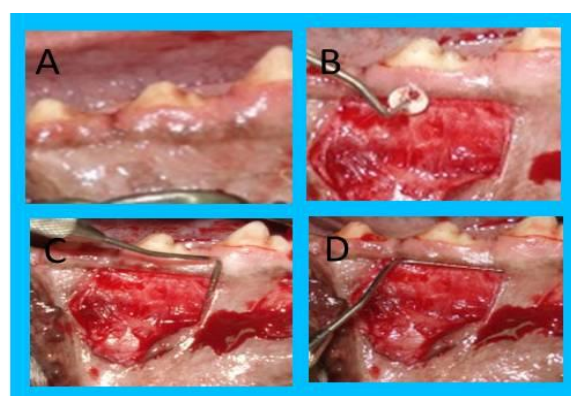


Figure 1. Clinical view before surgery (A), measuring of gingival thickness using a periodontal probe with rubber stop at mucogingival junction (B), vertical dimension of prepared bed (10 mm) (C), horizontal dimension of prepared bed (15 mm) (D)

The surgical operation: All surgical operations were performed in Department of Clinical Sciences, School of Veterinary Medicine, Shahid Bahonar University of Kerman. The dogs under study were anesthetized using 15 mg/kg of sodium pentobarbital (Chemidarou, Tehran, Iran) and then 1%-2.5% of halothane (Iran-Daroo, Tehran, Iran). During the surgery, the dogs were administered an intravenous dose of ringer lactate serum (5 ml/kg/hour). After general anesthesia, the sites of operation were anesthetized with lidocaine 2% containing epinephrine 1/80000 (Aburaihan, Tehran, Iran).

Overall, 64 sites (32 sites with preservation of periosteum and 32 sites with denudation technique) underwent the surgery. In design of this study, 2 sites in each quadrant of the mouth of dogs (4 sites in each side of the mouth of dogs) were operated. One side with periosteal fenestration technique and the other side with denudation technique (Figure 2). The operated sides were selected with throwing a coin (simple randomization). The periosteal fenestration technique was used to prepare the bed for half of the sites under study. While maintaining the marginal gingiva, a coronal (submarginal) incision was made by a surgical scalpel blade No. 15 in the mucogingival junction and vertical incisions at 15 mm intervals were made to both ends of the horizontal incision (Figure 1). The partial thickness flap was elevated and periosteal fenestration was performed at 6 mm distance of the coronal margin of the recipient bed on the preserved periosteum. An aluminum foil of the same dimensions was placed on the prepared bed. A crisscross horizontal mattress suture was then stitched to stabilize the aluminum foil. For the other sites, denudation technique was used. Similar to periosteal fenestration technique, the bed was prepared but without preserving the periosteum (Figure 2). With a periosteal elevator, a blunt dissection was performed to expose the bone. After this step, an aluminum foil with appropriate size was

placed on the bed and sutured. All surgical procedures were done by a periodontist who was not blind to this study.

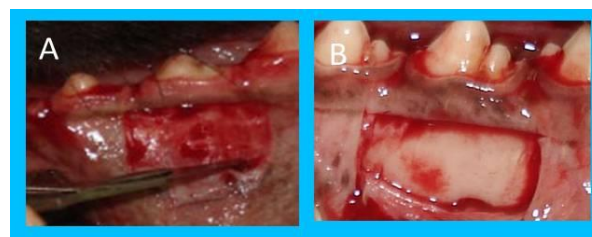

Figure 2. Periosteal fenestration bed (A) and denuded bed (B)

Postoperative care: The dogs went on a soft food diet for two weeks after the surgery. After the two-week period ended, the dogs returned to their normal diet. At the first day of surgery, 20 mg/kg of cefazolin sodium (Dana, Tabriz, Iran) was injected intramuscularly. Oral hygiene was maintained through weekly application of 0.2% chlorohexidine solution (Shahredaru, Tehran, Iran) to control infection for one month.

Postoperative measurements: The postoperative evaluation was performed 3 months after the surgery. The examined dogs were anesthetized using 15 mg/kg of sodium pentobarbital and then 1%-2.5% mg/kg of halothane. The keratinized gingival width at the mid-buccal area and the depth of the gingival sulcus restored after treatment on the mid-buccal area were measured by a clinician who was blind to this study, using a Williams probe with 1 mm accuracy. The attached gingiva width on the mid-buccal area was measured by subtracting the depth of the gingival sulcus from the keratinized gingiva width of the area.

The mean and standard deviation of pre-treatment data and post-treatment results were calculated. The data were not distributed normally as demonstrated by one sample Kolmogorov-Smirnov test. Therefore, Wilcoxon test was used to analyze the data before and after operation in each group and Mann-Whitney U test was used to analyze the clinical parameters between the two groups.

Table 1. Clinical parameters before and 2 months after surgery

Technique	Clinical parameter (mm)	Baseline	Two months after surgery	P
		(mean ± SD)	(mean ± SD)	
Periosteal fenestration	Width of keratinized gingiva	4.80 ± 1.42	6.60 ± 1.84	< 0.001
	Probing depth	1.50 ± 0.76	1.20 ± 0.47	0.100
	Width of attached gingiva	3.30 ± 1.60	5.30 ± 1.94	< 0.001
Denudation	Width of keratinized gingiva	4.70 ± 1.36	6.60 ± 1.89	< 0.001
	Probing depth	1.40 ± 0.61	1.10 ± 0.39	0.090
	Width of attached gingiva	3.20 ± 1.47	5.50 ± 2.00	< 0.001

SD: Standard deviation

Spearman rank correlation test was used to assess the correlation between the thickness of gingiva and the width of keratinized and attached gingiva in each group two months after surgery.

Results

The values of clinical parameters involving probing pocket depth, width of keratinized gingiva and width of attached gingiva at baseline and 2 months post-surgery are shown in table 1 and comparison of post-surgery clinical parameters between the two techniques is reported in table 2. These results showed the average of the increased width of keratinized and attached gingiva was 1.8 mm and 2 mm in periosteal fenestration sites, and 1.9 mm and 2.3 mm in denudation sites, respectively at 2 months post-surgery. The difference between the width of keratinized gingiva and attached gingiva before and 2 months after the surgery in both groups was significant ($P < 0.001$) (Table 1). The comparison between post-surgery width of keratinized and attached gingiva between these two techniques did not show any statistical difference ($P = 0.100$, $P = 0.720$, respectively) (Table 2).

The thickness of gingiva evaluated in this study was 0.8-2 mm. Based on the correlation analysis, there was not any correlation between the thickness of gingiva before

surgery and the amount of increased width of attached and keratinized gingiva after 2 months of surgery in periosteal fenestration and denuded sites.

Discussion

This study was conducted in order to assess the effect of gingival thickness on increasing the width of keratinized and attached gingiva.

The results of this study reported that significant increased width of keratinized and attached gingiva was obtained 2 months post-surgery with performing both denudation and periosteal fenestration techniques ($P < 0.001$).

Carranza and Carraro revealed an increased width of keratinized gingiva of 2.30 ± 0.38 mm using periosteal fenestration, which was more than the 1.8 mm augmentation rate obtained in the present study.²¹ Given that their study was also performed on dogs, the difference might be due to the larger dimensions of their prepared bed (15-20 mm vertical incision from the gingival margin); and removal of a 3-6 mm wide strip from the apical periosteum of the prepared bed.

Allen and Shell examined changes in keratinized gingival width in addition to vestibular depth through periosteal fenestration.²²

Table 2. Comparison of post-surgery clinical parameters between the two techniques

Clinical parameter	Post-surgery (mean ± SD)		P
	Periosteal fenestration	Denudation	
Width of keratinized gingiva	6.60 ± 1.84	6.60 ± 1.89	0.720
Probing depth	1.20 ± 0.47	1.10 ± 0.39	0.560
Width of attached gingiva	5.30 ± 1.94	5.50 ± 2.00	0.100

SD: Standard deviation

They revealed a keratinized gingival extension rate of 2.3 mm 40 weeks after periosteal fenestration, which was higher than the keratinized gingival extension rate of 1.8 mm obtained in the present study. This difference might be the bed prepared in their study that involved the entire mandibular anterior sextant (a horizontal incision on the mucogingival junction and two 10 mm vertical incisions on the mandibular canine area). Therefore, the dimensions of their prepared bed were larger than the one in the present study.

Bowers reported an attached gingival extension rate of 2.3 mm after periosteal fenestration which was almost similar to this study (2 mm).²³

In the study conducted by Mohammadi et al. the attached gingival extension rate after periosteal fenestration was reported 1.9 mm.¹³ The attached gingival extension rate after periosteal fenestration was reported 2 mm in the present study. Given the studies performed periosteal fenestration, results of the study conducted by Mohammadi et al. closely resembled the results of the present study, which might be due to similar conditions of preparing the surgery bed. Mohammadi et al.¹³ performed periosteal fenestration on humans, while the present study performed the technique on dogs. The dimensions of the recipient bed may be a factor affecting clinical results of periosteal fenestration technique. The reason might be that larger dimensions of the prepared bed, in particular the vertical dimension, help the fibroblast cells of the keratinized tissue to have more time for their apical motion on the prepared bed. Moreover, muscle attachment for developing vestibular depth will probably take longer too. The outcome of these two events is the formation of more keratinized and attached tissue.

Carraro et al. evaluated the effect of bone denudation in mucogingival surgery in a human study.¹⁹ They concluded that the increased width of attached gingiva in sites with preserved periosteum is significantly

more than the denuded sites.¹⁹ The difference of the width of the attached gingiva between denuded sites and periosteal retention sites was 0.6 mm, but this difference in present study was 0.1 mm. The difference in coronal incision (marginal in the mentioned study but submarginal in our study) can explain this. Based on the results of these two studies, when we have a marginal incision along with denudation, less attached gingiva will be created because of bone resorption and gingival recession, in comparison with periosteal retention sites. But in prepared sites with submarginal incisions, the amount of new created attached gingiva in denuded and periosteal retention sites is similar. These results show that the apical migration of mucogingival line is similar in both studies.

On one hand, thick gingiva has a larger amount of extracellular matrix, collagen and fibroblast cells compared to thin gingiva; on the other, it has a larger volume of blood vessels.²⁴⁻²⁶ The larger volume of blood vessels causes higher tissue oxygenation, higher and better elimination of toxic products, better immune response and migration of more growth factors in the tissue.²⁴⁻²⁶ Given the tissue properties of thick gingiva, the researchers decided to examine the effect of the thickness of gingiva on the amount of gingival augmentation with and without preservation of periosteum. The results of the present study did not show any correlation between gingival thickness and the amount of increased width of attached and keratinized gingiva in both groups within 2 months of the surgery. The gingival thickness evaluated in the present study was between 0.8 and 2 mm in both groups. Given results of the present study and also the fact that no similar studies have yet been performed on this topic, it can be concluded that a gingival thickness of 0.8 to 2 mm does not affect attached and keratinized gingival extension rates.

Conclusion

Based on the results of this study, there is not any correlation between the gingival thickness of 0.8-2 mm at mucogingival

junction and the amount of increased width of keratinized and attached gingiva in periosteal fenestration and denuded sites.

Conflict of Interests

Authors have no conflict of interest.

Acknowledgments

This study was supported by a grant from Kerman Oral and Dental Researches Center, Kerman University of Medical Sciences and School of Veterinary Medicine, Shahid Bahonar University of Kerman.

References

1. Newman M, Takei H, Klokkevold P, Carranza FA, Jr. Carranza's clinical periodontology. 12th ed. Philadelphia, PA: Saunders; 2014. p. 628.
2. Carranza FA, Jr., Carraro JJ. Mucogingival techniques in periodontal surgery. *J Periodontol* 1970; 41(5): 294-9.
3. Ericsson I, Lindhe J. Recession in sites with inadequate width of the keratinized gingiva. An experimental study in the dog. *J Clin Periodontol* 1984; 11(2): 95-103.
4. Stetler KJ, Bissada NF. Significance of the width of keratinized gingiva on the periodontal status of teeth with submarginal restorations. *J Periodontol* 1987; 58(10): 696-700.
5. Ochsenein C. Newer concepts of mucogingival surgery. *J Periodontol* 1960; 31(3): 175-85.
6. Corn H. Periosteal separation—its clinical significance. *J Periodontol* 1962; 33(2): 140-53.
7. Wilderman MN. Repair after a periosteal retention procedure. *J Periodontol* 1963; 34(6): 487-503.
8. Robinson RE, Agnew RG. Periosteal fenestration at the mucogingival line. *J Periodontol* 1963; 34(6): 503-12.
9. Edel A. Clinical evaluation of free connective tissue grafts used to increase the width of keratinised gingiva. *J Clin Periodontol* 1974; 1(4): 185-96.
10. Bjorn H. Free transplantation of gingiva propria. *Sveriges Tandlakt* 1963; 22: 684-8.
11. Silverstein L, Callan D. An acellular dermal matrix allograft and a palatal graft for tissue augmentation. *Periodontal Insights* 1996; 6: 3-6.
12. McGuire MK, Nunn ME. Evaluation of the safety and efficacy of periodontal applications of a living tissue-engineered human fibroblast-derived dermal substitute. I. Comparison to the gingival autograft: a randomized controlled pilot study. *J Periodontol* 2005; 76(6): 867-80.
13. Mohammadi M, Shokrgozar MA, Mofid R. Culture of human gingival fibroblasts on a biodegradable scaffold and evaluation of its effect on attached gingiva: a randomized, controlled pilot study. *J Periodontol* 2007; 78(10): 1897-903.
14. Harris RJ. A comparative study of root coverage obtained with guided tissue regeneration utilizing a bioabsorbable membrane versus the connective tissue with partial-thickness double pedicle graft. *J Periodontol* 1997; 68(8): 779-90.
15. Muller HP, Stahl M, Eger T. Dynamics of mucosal dimensions after root coverage with a bioresorbable membrane. *J Clin Periodontol* 2000; 27(1): 1-8.
16. Brasher WJ, Rees TD, Boyce WA. Complications of free grafts of masticatory mucosa. *J Periodontol* 1975; 46(3): 133-8.
17. Raghoebar GM, Tomson AM, Scholma J, Blaauw EH, Witjes MJ, Vissink A. Use of cultured mucosal grafts to cover defects caused by vestibuloplasty: an in vivo study. *J Oral Maxillofac Surg* 1995; 53(8): 872-8.
18. Ueda M, Hata KI, Sumi Y, Mizuno H, Niimi A. Peri-implant soft tissue management through use of cultured mucosal epithelium. *Oral Surg Oral Med Oral Pathol Oral Radiol Endod* 1998; 86(4): 393-400.
19. Carraro JJ, Carranza FA, Jr., Albano EA, Joly GG. Effect of bone denudation in mucogingival surgery in humans. *J Periodontol* 1964; 35(6): 463-6.
20. Struillou X, Boutigny H, Soueidan A, Layrolle P. Experimental animal models in periodontology: a review. *Open Dent J* 2010; 4: 37-47.
21. Carranza FA, Jr., Carraro JJ. Effect of removal of periosteum on postoperative result of mucogingival surgery. *J Periodontol* 1963; 34(3): 223-6.
22. Allen DL, Shell JH. Clinical and radiographic evaluation of a periosteal separation procedure. *J Periodontol* 1968; 39(5): 290-5.
23. Bowers GM. A study of the width of attached gingiva. *J Periodontol* 1963; 34(3): 201-9.
24. Folke LE, Stallard RE. Periodontal microcirculation as revealed by plastic microspheres. *J Periodontal Res* 1967; 2(1): 53-63.
25. Keller GJ, Cohen DW. India ink perfusions of the vascular plexus of oral tissues. *Oral Surg Oral Med Oral Pathol* 1955; 8(5): 539-42.
26. Mormann W, Ciancio SG. Blood supply of human gingiva following periodontal surgery. A fluorescein angiographic study. *J Periodontol* 1977; 48(11): 681-92.