

## A 25-year retrospective epidemiological study of intra-osseous lesions of jaw bones in Isfahan population, Iran

Sayed Mohammad Razavi DDS<sup>1</sup>, Mohammad Ansari DDS<sup>2</sup>,  
Saeedeh Khalesi DDS<sup>3</sup>

### Original Article

#### Abstract

**BACKGROUND AND AIM:** Intra-osseous pathologic lesions of the jaw bones have different radiological and clinicopathological features from benign to malignant lesions. The aim of this study was to determine the prevalence of jaw lesions in Isfahan, Iran, during 1992-2017.

**METHODS:** In this descriptive-analytical study, all records of intra-osseous jaw lesions were investigated. All information of patients such as age, gender, location of lesion, radiographic feature, and histopathological diagnosis was collected. The lesions were divided to 7 groups including inflammatory periapical lesions, developmental odontogenic cysts, odontogenic tumors, benign non-odontogenic bone lesions, malignant bone tumors, developmental lesions, and others. The obtained data were analyzed with SPSS software, using chi-square test and Fisher's exact test.

**RESULTS:** A total of 1064 intra-osseous jaw lesions were evaluated. The mean age of patients with these lesions was  $30.6 \pm 15.1$  years with the male to female ratio of 1.3:1. The most prevalent jaw lesions were inflammatory periapical lesions (49.9%), developmental odontogenic cysts (33.2%), benign non-odontogenic bone lesions (8.0%), odontogenic tumors (6.2%), developmental lesions (1.2%), malignant bone tumors (0.9%), and others (0.6%). Posterior region of mandibular bone was more affected. The frequency of jaw pathologic lesions according to site of lesions and age was statistically significant ( $P < 0.05$ ), but no significant difference was observed based on gender ( $P > 0.050$ ). Radicular cyst, dentigerous cyst, and central giant cell granuloma (CGCG) were the most prevalent. The most radiographic view was radiolucent.

**CONCLUSION:** This study showed the clinicopathological information of intra-osseous jaw bone lesions in Isfahan population. Inflammatory periapical lesions, odontogenic cysts, and tumors were the most common intra-osseous jaw bone lesions. These results showed the importance of health education to patients for prevention of inflammatory periapical lesions.

**KEYWORDS:** Jaw; Radiography; Prevalence; Pathology

**Citation:** Razavi SM, Ansari M, Khalesi S. A 25-year retrospective epidemiological study of intra-osseous lesions of jaw bones in Isfahan population, Iran. *J Oral Health Oral Epidemiol* 2019; 8(2): 68-73.

Intra-osseous jaw lesions have different clinical, radiological, and histopathological features.<sup>1</sup> Clinical and radiographic features of the lesions help determine the differential diagnosis, but the final diagnosis is only possible by histopathologic examination.<sup>2</sup> Dental radiography is necessary for complete

clinical information.<sup>3</sup> According to radiological features, bone lesions were distributed to radiolucent, radiopaque, and a mix of both. Furthermore, these lesions might be around the root of teeth or crown of impacted teeth or might have no relation with teeth.<sup>4,5</sup>

Based on histopathological features, jaw

1- Professor, Dental Implant Research Center, Dental Research Institute AND Department of Oral and Maxillofacial Pathology, School of Dentistry, Isfahan University of Medical Sciences, Isfahan, Iran

2- Student of Dentistry, School of Dentistry, Isfahan University of Medical Sciences, Isfahan, Iran

3- Assistant Professor, Dental Implant Research Center, Dental Research Institute AND Department of Oral and Maxillofacial Pathology, School of Dentistry, Isfahan University of Medical Sciences, Isfahan, Iran

Correspondence to: Saeedeh Khalesi DDS

Email: s\_khalesi@dnt.mui.ac.ir

bone lesions can be categorized to inflammatory lesions, cysts, benign tumors, malignant lesions, and the osseous appearance of systemic disease. Although, in some studies, they were divided to odontogenic or non-odontogenic cysts, benign or malignant tumors, and developmental or reactive lesions.<sup>6</sup> The prevalence of jaw lesions is different in population groups due to the impact of racial and geographic factors.<sup>5,6</sup> In the most studies, odontogenic cysts were the most prevalent lesions;<sup>1,6,7</sup> but in some studies, reactive lesions had more frequency than cystic lesions.<sup>8</sup>

Considering the great effects of geographic and racial factors on the prevalence of lesions and the importance of their early detection to improve prognosis, the aim of this study was to determine the prevalence of jaw lesions in Isfahan, Iran, during 1992-2017.

### Methods

In this descriptive-analytical study, all records of jaw bone lesions from 1992-2017 registered in Department of Oral and Maxillofacial Pathology of Isfahan Dental School were investigated by a dentistry student of 12<sup>th</sup> semester. Before assessment of records of archive, the student was educated by an oral pathologist on how to extract information from registered records. All information of patients such as age, gender, location of lesion, radiographic feature

(radiolucent, radiopaque, mixed), differential diagnosis, and histopathological diagnosis was collected. The lesions were divided into 7 groups including inflammatory periapical lesions (group 1), developmental odontogenic cysts (group 2), odontogenic tumors (group 3), benign non-odontogenic bone lesions (group 4), malignant bone tumors (group 5), developmental lesions (group 6), and others (appearance of systemic disease, metastatic lesions) (group 7).<sup>1,6</sup> The obtained data were entered into SPSS software (version 21, IBM Corporation, Armonk, NY, USA) and analyzed by chi-square test. A P-value < 0.05 was considered significant.

### Results

In the current study, 1545 samples with intra-osseous jaw lesions were investigated in Isfahan Oral Pathology Department, of which 1064 samples were included. Due to a lack of information, 481 samples were excluded from the study. As for gender, 565 patients were male (53.1%) and 499 patients were female (46.9%). The male to female ratio was 1.3:1 and a non-significant difference based on chi-square test was observed ( $P = 0.058$ ). Mandibular involvement was 1.5 times greater than maxilla involvement; posterior jaw was more affected. This difference was significant by chi-square test ( $P = 0.050$ ). Table 1 shows the distribution of all samples based on clinical features of jaw lesions in seven groups of bone lesions.

**Table 1.** Distribution of intra-osseous lesions based on clinical features

Groups of bone lesions	Gender [n (%)]		Location [n (%)]				Age (year) (mean ± SD)	Total [n (%)]
	Male	Female	Anterior maxilla	Posterior maxilla	Anterior mandible	Posterior mandible		
Inflammatory periapical lesions	273 (51.4)	258 (48.6)	170 (32.0)	104 (19.5)	45 (8.5)	212 (40.0)	32.8 ± 13.6	531 (49.9)
Developmental odontogenic cysts	209 (59.2)	144 (40.8)	61 (17.2)	38 (10.7)	21 (6.0)	233 (66.1)	27.9 ± 16.8	353 (33.2)
Benign non-odontogenic bone lesions	36 (42.3)	49 (57.7)	6 (7.0)	11 (13.1)	10 (11.7)	58 (68.2)	28.1 ± 13.6	85 (8.0)
Odontogenic tumors	33 (50.0)	33 (50.0)	9 (13.6)	7 (10.7)	8 (12.1)	42 (63.6)	26.5 ± 13.5	66 (6.2)
Developmental lesions	6 (46.1)	7 (53.9)	7 (53.8)	5 (38.5)	1 (7.7)	0 (0)	44.7 ± 18.2	13 (1.2)
Malignant tumors	4 (40.0)	6 (60.0)	3 (30.0)	1 (10.0)	3 (30.0)	3 (30.0)	27.6 ± 11.1	10 (0.9)
Others	4 (66.6)	2 (33.4)	0 (0)	5 (83.3)	0 (0)	1 (16.7)	46.5 ± 20.5	6 (0.6)
<b>Total</b>	<b>565 (53.1)</b>	<b>499 (46.9)</b>	<b>256 (24.0)</b>	<b>171 (16.0)</b>	<b>88 (8.2)</b>	<b>549 (51.8)</b>	<b>30.6 ± 15.1</b>	<b>1064 (100)</b>

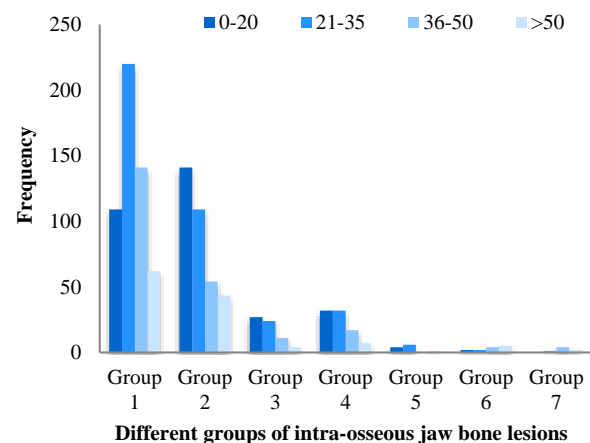
SD: Standard deviation

**Table 2.** Distribution of intra-osseous lesions based on radiographic features

Groups of bone lesions	Radiographic feature [n (%)]			
	Radiolucent	Radiopaque	Mixed	Total
Inflammatory periapical lesions	514 (96.8)	6 (1.2)	11 (2.0)	531 (49.9)
Developmental odontogenic cysts	345 (97.8)	2 (0.5)	6 (1.7)	353 (33.2)
Benign non-odontogenic bone lesions	65 (76.4)	8 (9.4)	12 (14.2)	85 (8.0)
Odontogenic tumors	38 (57.7)	16 (24.2)	12 (18.1)	66 (6.2)
Developmental lesions	13 (100)	0 (0)	0 (0)	13 (1.2)
Malignant tumors	8 (80.0)	0 (0)	2 (20.0)	10 (0.9)
Others	4 (66.7)	2 (33.3)	0 (0)	6 (0.6)
Total	987 (92.7)	34 (3.1)	43 (4.2)	1064 (100)

The patients' age ranged from 4 to 84 years and the average age was  $30.6 \pm 15.1$  years. Based on chi-square test, the difference of frequency in patients' age between seven groups of bone lesions was statistically significant ( $P < 0.001$ ). The prevalence of the group 1 lesions was more frequent in patients of 21-35 years old. In addition, most of the odontogenic cysts and tumors were seen in first and second decades. Benign non-odontogenic bone lesions were seen equally in the patients of 0-20 and 21-35 years old. The patients of 21 to 35 years old had the highest incidence of malignant bone tumors. The frequency of developmental lesions was higher in the age of 50 (Figure 1). Table 2 presents the frequency of different intra-osseous lesions based on radiographic features. The difference between radiopaque and radiolucent features was statistically significant; furthermore, there was a significant difference between seven groups of bone lesions based on chi-square test ( $P < 0.001$ ). There was also a significant

difference between the radiolucent and mixed view ( $P < 0.001$ ). However, the differences between radiopaque and mixed features in groups of study was not statistically significant ( $P = 0.120$ ). Most of jaw bone lesions (92.7%) had radiolucent feature. Three most common lesions of each group are shown in table 3. Inflammatory periapical lesions were the most frequent among the jaw lesions (49.9%).

**Figure 1.** Frequency of intra-osseous jaw bone lesions based on different age groups**Table 3.** Distribution of three most common lesions in each group

Groups of bone lesions	Histopathologic diagnosis		
	First [n (%)]	Second [n (%)]	Third [n (%)]
Inflammatory periapical lesions	Radicular cyst: 376 (70.8)	Dental granuloma: 144 (27.1)	Osteomyelitis: 7 (1.3)
Developmental odontogenic cysts	Dentigerous cyst: 228 (64.5)	OKC: 101 (28.6)	COC: 7 (2.0)
Odontogenic tumors	Odontoma: 25 (37.8)	Ameloblastoma: 22 (33.3)	AOT : 6 (9.0)
Benign non-odontogenic bone lesions	CGCG: 28 (33.0)	Fibro-osseous lesions: 24 (28.2)	Osteoma: 5 (5.8)
Malignant tumors	Osteosarcoma: 4 (40.0)	Langerhans cell disease: 3 (30.0)	Chondrosarcoma: 2 (20.0)
Developmental lesions	NPDC: 13 (100)	-	-
Others	Antral pseudocyst: 6 (100)	-	-

CGCG: Central giant cell granuloma; NPDC: Nasopalatine duct cyst; AOT: Adenomatoid odontogenic tumor; COC: Calcifying odontogenic cyst; OKC: Odontogenic keratocyst

Malignant tumors [including osteosarcoma, chondrosarcoma, intra-osseous mucoepidermoid carcinoma (MEC)] and others (appearance of systemic disease, metastatic lesions) had the least prevalence among lesions. The most common lesions in the groups were radicular cyst (group 1), dentigerous cyst (group 2), central giant cell granuloma (CGCG) (group 3), odontoma (group 4), nasopalatine duct cyst (NPDC) (group 5), osteosarcoma (group 6), and antral pseudocyst (group 7).

The Cohen's kappa coefficient between clinical differential diagnosis and histopathological diagnosis was 70.0%. The concordance of diagnosis was relatively good compared to the primary and final diagnosis, but not desirable.

### Discussion

In the present study, 1064 intra-osseous jaw lesions were evaluated. Based on our results, inflammatory periapical lesions (49.9%) were the most common jaw lesions. Comparing these results with other studies is difficult because the jaw bone groups are different in different studies. Most studies, such as Jamshidi et al.,<sup>6</sup> Peker et al.,<sup>7</sup> Mendez et al.,<sup>8</sup> Ali,<sup>9</sup> Al Yamani et al.,<sup>10</sup> and other studies have shown that cystic lesions are the most commonly-reported jaw lesions. In this study, the second most common lesions were odontogenic cysts (33.2%), but in Jamshidi et al.<sup>6</sup> and Ali<sup>9</sup> studies, inflammatory lesions had higher prevalence than other lesions in Iran and Kuwait populations, respectively. Jaafari-Ashkavandi and Akbari reported that benign jaw bone lesions were the second greatest lesions in southern Iranian population.<sup>1</sup> In the present study, radicular cysts had the most frequency of intra-osseous jaw lesions followed by dentigerous cyst, dental granuloma, and odontogenic keratocyst (OKC), that was similar to other studies.<sup>1,2,7,9,11,12</sup> However, Jamshidi et al. study showed the higher prevalence of OKCs than dentigerous cysts.<sup>6</sup>

Odontoma and ameloblastoma had the

highest incidence of odontogenic tumors in this study. This result is consistent with reports of Peker et al.<sup>7</sup> and Gaitan-Cepeda et al.<sup>13</sup> in Turkey and Mexico, respectively. However, some studies reported the higher prevalence of ameloblastoma than odontoma.<sup>1,6,14</sup>

Consistent with the other studies, we found that CGCG and fibro-osseous lesions, respectively, were the most common benign jaw bone lesions.<sup>1,2,6,15</sup> In contrast to this result, Peker et al.<sup>7</sup> and Lei et al.<sup>12</sup> reported the higher occurrence of fibro-osseous lesions in Turkish and Taiwanese patients, respectively.

Only 0.9% of all intra-osseous jaw lesions were malignant tumors in the present study. Osteosarcoma was the most malignant jaw tumor, that was similar to other studies.<sup>1,6,16</sup> In contrast to these results, Jaafari-Ashkavandi and Akbari,<sup>1</sup> Koivisto et al.,<sup>2</sup> and Ali<sup>9</sup> indicated the higher prevalence of malignant tumors.

According to the present study, the intra-osseous jaw lesions had a slightly male predominance that was similar to other studies.<sup>1,6,7,15</sup> Benign bone lesions, malignant tumor, and developmental lesions had higher prevalence in females. Some studies have shown that odontogenic tumors are more common in women than in men.<sup>7,13,17</sup> In our study, these lesions were equally distributed.

In the current study, the total average age was 30.6 years, but in Jaafari-Ashkavandi and Akbari<sup>1</sup> study, it was reported 30.1 years, in Jamshidi et al.<sup>6</sup> 29.6 years, in Peker et al.<sup>7</sup> 42.0 years, and in Javadian et al.<sup>14</sup> 36.0 years. Our study showed that the intra-osseous lesions had occurred in younger patients in Isfahan population in comparison with other populations. Furthermore, developmental lesions and malignant tumors mostly affected the older patients, that was similar to Jamshidi et al.<sup>6</sup> study.

In all diagnostic groups of lesions, the posterior region of mandibular bone was the most location of involvement, that was similar to other studies.<sup>1,6,9,15</sup> However, the developmental lesions such as NPDC occurred in anterior region of maxillary bone. The nature

of these lesions is the reason for this.

According to radiographic features, the lesions of current study were radiolucent, mixed, and radiopaque, respectively, that was different from Bernaerts et al.<sup>18</sup> and Hosseini Zarch et al.<sup>19</sup> studies in Belgium and Iran, respectively. However, this result resemble the report of Jamshidi et al.<sup>6</sup>

The compliance of the diagnosis as a result of the comparison of clinical and final diagnosis was 70.0% in our study, although this concordance was 80.5% in Peker et al.<sup>7</sup> study. Regarding the clinical and radiographic similarities between radical cysts and periapical granulomas (PGs), these lesions have the majority of the diagnostic disagreements. The pathologic process is similar to these two lesions due to the reasons behind these results.<sup>7,20</sup> However, these differences may be due to the interpretation of the clinical presentation and radiography of jaw lesions.<sup>7</sup>

It seems that racial and geographic factors affect the clinical, radiographic, and histopathological features of intra-osseous jaw lesions. However, different design and sample size of studies were important in

results. The limitations of present study were the lack of access to the radiographs. Defects in clinical and radiographic records show the importance of recording all information. Furthermore, if all slides of the samples were examined by histopathologic features for checking the diagnosis, the study accuracy would increase.

### Conclusion

The current study showed the clinicopathological information of intra-osseous jaw bone lesions in Isfahan population. Inflammatory periapical lesions, odontogenic cysts, and tumors were the most common intra-osseous jaw bone lesions. These results showed the importance of health education to patients for prevention of inflammatory periapical lesions.

### Conflict of Interests

Authors have no conflict of interest.

### Acknowledgments

The authors are grateful to the Vice Chancellor for Research of Isfahan University of Medical Sciences for the financial support provided.

### References

1. Jaafari-Ashkavandi Z, Akbari B. Clinicopathologic study of intra- osseous lesions of the jaws in southern Iranian population. *J Dent (Shiraz)* 2017; 18(4): 259-64.
2. Koivisto T, Bowles WR, Rohrer M. Frequency and distribution of radiolucent jaw lesions: A retrospective analysis of 9,723 cases. *J Endod* 2012; 38(6): 729-32.
3. White SC, Scarfe WC, Schulze RK, Lurie AG, Douglass JM, Farman AG, et al. The Image Gently in Dentistry campaign: Promotion of responsible use of maxillofacial radiology in dentistry for children. *Oral Surg Oral Med Oral Pathol Oral Radiol* 2014; 118(3): 257-61.
4. Gijbels F, Jacobs R, Bogaerts R, Debaveye D, Verlinden S, Sanderink G. Dosimetry of digital panoramic imaging. Part I: Patient exposure. *Dentomaxillofac Radiol* 2005; 34(3): 145-9.
5. Tortorici S, Amodio E, Massenti MF, Buzzanca ML, Burrano F, Vitale F. Prevalence and distribution of odontogenic cysts in Sicily: 1986-2005. *J Oral Sci* 2008; 50(1): 15-8.
6. Jamshidi S, Shojaei S, Roshanaei G, Modabbernia S, Bakhtiary E. Jaw intraosseous lesions biopsied extracted from 1998 to 2010 in an Iranian population. *Iran Red Crescent Med J* 2015; 17(6): e20374.
7. Peker E, Ogutlu F, Karaca IR, Gultekin ES, Cakir M. A 5 year retrospective study of biopsied jaw lesions with the assessment of concordance between clinical and histopathological diagnoses. *J Oral Maxillofac Pathol* 2016; 20(1): 78-85.
8. Mendez M, Carrard VC, Haas AN, Lauxen IS, Barbachan JJ, Rados PV, et al. A 10-year study of specimens submitted to oral pathology laboratory analysis: Lesion occurrence and demographic features. *Braz Oral Res* 2012; 26(3): 235-41.
9. Ali MA. Biopsied jaw lesions in Kuwait: A six-year retrospective analysis. *Med Princ Pract* 2011; 20(6): 550-5.
10. Al Yamani AO, Al Sebaei MO, Bassyoni LJ, Badghaish AJ, Shawly HH. Variation of pediatric and adolescents head and neck pathology in the city of Jeddah: A retrospective analysis over 10 years. *Saudi Dent J* 2011; 23(4): 197-200.
11. Nunez-Urrutia S, Figueiredo R, Gay-Escoda C. Retrospective clinicopathological study of 418 odontogenic cysts. *Med Oral Patol Oral Cir Bucal* 2010; 15(5): e767-e773.

12. Lei F, Chen PH, Chen JY, Wang WC, Lin LM, Huang HC, et al. Retrospective study of biopsied head and neck lesions in a cohort of referral Taiwanese patients. *Head Face Med* 2014; 10: 28.
13. Gaitan-Cepeda LA, Quezada-Rivera D, Tenorio-Rocha F, Leyva-Huerta ER. Reclassification of odontogenic keratocyst as tumour. Impact on the odontogenic tumours prevalence. *Oral Dis* 2010; 16(2): 185-7.
14. Javadian LA, Lari SS, Shokri A, Hoseini Zarch SH, Jamshidi S, Akbari P. Intraosseous benign lesions of the jaws: a radiographic study. *Iran J Radiol* 2014; 11(1): e7683.
15. Johnson NR, Savage NW, Kazoullis S, Batstone MD. A prospective epidemiological study for odontogenic and non-odontogenic lesions of the maxilla and mandible in Queensland. *Oral Surg Oral Med Oral Pathol Oral Radiol* 2013; 115(4): 515-22.
16. Vadillo RM, Contreras SJ, Canales JO. Prognostic factors in patients with jaw sarcomas. *Braz Oral Res* 2011; 25(5): 421-6.
17. Alsufyani NA, Lam EW. Cemento-osseous dysplasia of the jaw bones: Key radiographic features. *Dentomaxillofac Radiol* 2011; 40(3): 141-6.
18. Bernaerts A, Vanhoenacker FM, Hintjens J, Chapelle K, Salgado R, De Foer B, et al. Tumors and tumor-like lesions of the jaw mixed and radiopaque lesions. *JBR -BTR* 2006; 89(2): 91-9.
19. Hosseini Zarch SH, Javadian Langroudi A, Tavasouli Noughabi A. Accuracy of conventional radiography in differentiating between benign lesions and malignant ones in the maxillofacial region. *J Mashad Dent Sch* 2009; 33(2): 121-8. [In Persian].
20. Lia RC, Garcia JM, Sousa-Neto MD, Saquy PC, Marins RH, Zuccolotto WG. Clinical, radiographic and histological evaluation of chronic periapical inflammatory lesions. *J Appl Oral Sci* 2004; 12(2): 117-20.